

Letter to Editor

Isolated trigeminal sensory neuropathy

Otto Hernandez Fustes¹, Georgette Mouchaileh E. Ferreira²

¹Department of Neurology, Complexo Hospital de Clínicas da UFPR, ²Department of Neurology, Hospital das Nações, Curitiba, Brazil.

Dear Editor,

We highlight the importance of clinical history and complementary examinations that are necessary in diagnosing infrequent pain syndromes. We describe a 58-year-old woman who presented with a 4-day history of pain on the right side of the facial and tongue hypoesthesia that was accompanied by dysesthesias.

Brain magnetic resonance imaging (MRI) scan showed the presence of lesions with contrast enhancement, compromising the topography of the right trigeminal nucleus and the left trigeminal nerve at the level of its emergence [Figure 1]. The rest of the neurological examination was normal. After treatment with methylprednisolone IV for 3 days, the condition of the patient evidently improved.

Trigeminal sensory neuropathy (TSN) is characterized by numbness on the skin or mucosal membranes in the distribution of the trigeminal nerves or weakness in the muscles of mastication. This condition has received attention in only a few case reports and main studies.^[1]

A spectrum of pathophysiological processes may affect the trigeminal nerves, including traumatic, vascular, demyelinating, infectious, neoplastic, and inflammatory disorders. This is similar to our patient who appeared to have a probable condition of lupus erythematosus after a thorough investigation.

Lecky and colleagues reported patients with idiopathic sensory disturbances restricted to the trigeminal territory and referred to this condition as "idiopathic TSN."^[2]

Recent onset of bilateral trigeminal sensory hypoesthesia may subsequently follow one of the two clinical courses: In some patients, the disease will remain isolated to TSN, while in others, it will progress to facial onset sensory and TSN.^[3]

MRI is a valid method to investigate TSN, although its sensitivity and specificity seem variable, resulting in false positives and false negatives.^[4] Therefore, the relationship between the neuroradiological findings and the clinical

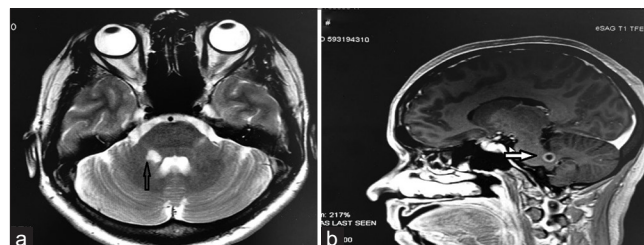


Figure 1: (a and b) Brain MRI with the presence of T2 hyperintense lesion with ring enhancement in the topography of the transition between the bridge and the right middle cerebellar peduncle and signs of increased signal intensity with thickening and enhancement by means of contrast of the left trigeminal nerve and at the level of its path at the level of the transition between the bridge and the left middle cerebellar peduncle.

picture is important and must be individualized to each patient.

Neuroimaging is useful in the diagnostic workup of TSN. Ruling out other causes of pain, such as space-occupying lesions, is important and requires an approach that is more specific than simply empiric medications.^[5]

Declaration of patient consent

The authors certify that they have obtained all appropriate patient consent.

Financial support and sponsorship

Nil.

Conflicts of interest

There are no conflicts of interest.

REFERENCES

1. Spillane JD, Wells CE. Isolated trigeminal neuropathy. A report of 16 cases. *Brain* 1959;82:391-416.

*Corresponding author: Otto Hernandez Fustes, Department of Neurology, Complexo Hospital de Clínicas da UFPR, Rua General Carneiro 181, 80060-900, Curitiba, Brazil. otto.fustes@hc.ufpr.br

Received: 12 September 2022 Accepted: 05 October 2022 Epub Ahead of Print: 29 October 2022 Published: XXXXXX DOI: 10.25259/JNRP-2022-7-29

This is an open-access article distributed under the terms of the Creative Commons Attribution-Non Commercial-Share Alike 4.0 License, which allows others to remix, transform, and build upon the work non-commercially, as long as the author is credited and the new creations are licensed under the identical terms. ©2022 Published by Scientific Scholar on behalf of Journal of Neurosciences in Rural Practice

2. Lecky BR, Hughes RA, Murray NM. Trigeminal sensory neuropathy. A study of 22 cases. *Brain* 1987;110:1463-85.
3. Cruccu G, Pennisi EM, Antonini G, Biasiotta A, di Stefano G, La Cesa S, *et al.* Trigeminal isolated sensory neuropathy (TISN) and FOSMN syndrome: Despite a dissimilar disease course do they share common pathophysiological mechanisms? *BMC Neurol* 2014;14:248.
4. Siccoli MM, Bassetti CL, Sándor PS. Facial pain: Clinical differential diagnosis. *Lancet Neurol* 2006;5:257-67.
5. Filho PT, Poliseli GB, Oliveira VA, Vital RB, Lima MM, Bazan R, *et al.* Unusual painful trigeminal neuropathy caused by racemose neurocysticercosis. *Pain Med* 2016;17:992-4.

How to cite this article: Fustes OH, Ferreira GM. Isolated trigeminal sensory neuropathy. *J Neurosci Rural Pract*, doi: 10.25259/JNRP-2022-7-29