

Case Series

# Calvarial tuberculosis – A report of seven cases from a tertiary care hospital

Santhanam Rengarajan<sup>1</sup> , Lakshmi Krishnasamy<sup>2</sup>

Departments of <sup>1</sup>Neurosurgery and <sup>2</sup>Microbiology, Sree Balaji Medical College and Hospital, Bharath Institute of Higher Education and Research, Chennai, Tamil Nadu, India.

## ABSTRACT

Tuberculosis primarily affecting the calvarium is one of the rare diseases which is on the rise in the past few decades. This disease has been rarely reported in the literature even from endemic regions. We report seven patients diagnosed with calvarial tuberculosis. All cases had histological features of tuberculosis and were mantoux positive. All were negative for AFB smears. Two out of four cases tested for TB GeneXpert were positive. The clinical presentations, radiological features and the management of the cases are discussed. Early diagnosis with high index of suspicion and awareness about the features of calvarial tuberculosis would help in proper management of the condition.

**Keywords:** Calvarial tuberculosis, Antitubercular therapy, Surgical excision

## INTRODUCTION

Tuberculosis is one of the infectious diseases significantly affecting the economy in developing countries like India. Tuberculosis involving the calvaria is rare but is being increasingly reported of late in the recent decades due to poor socioeconomic status, overcrowding, malnourishment, lack of hygiene and sanitation, delay in initiation of treatment, etc.

The incidence rate of tuberculosis skull is 0.2–1.3% among the skeletal tuberculosis.<sup>[1]</sup> Since the cancellous bone in the skull is usually lesser in infants, this condition is rare in infants <1 year. Accurate and prompt diagnosis of tuberculous involvement of skull bone needs awareness and high index of suspicion.

We report seven cases of calvarial tuberculosis. The clinical presentations, radiological features, and management of the cases are briefly discussed.

## MATERIALS AND METHODS

This is a retrospective study conducted in the department of neurosurgery, in a tertiary care hospital in Chennai, over a period of 15 years. Patients of age group 28–80 years attending the neurosurgery OPD were included in the study. Case records of seven patients diagnosed with calvarial tuberculosis were analyzed retrospectively. Those

with contiguous or coexisting craniovertebral junction or cervical spinal involvement were excluded from the study. Patient data including their presenting complaints, clinical evaluation, laboratory investigations, and radiological findings were analyzed. The results were compared with the existing literature.

## RESULTS

During the study period of 15 years, seven cases of TB skull were admitted in the neurosurgery ward [Table 1]. Age ranged from 28 years to 80 years. Out of the seven patients, six patients were male.

Swelling in the scalp is the common presenting symptom in the patients followed by pain. Frontoparietal regions were involved in four cases and occipital or parieto-occipital region was involved in three cases. The swelling in the scalp was found to be non-tender in four patients and mild-to-moderate tenderness was seen in the other three patients. Right 9, 10, 11, and 12 cranial nerve palsy was observed in one patient. One patient presented with discharging scalp sinus.

The debrided osteomyelitic bone and soft tissue were sent for histopathological examination (HPE). All cases revealed histological evidence of tuberculosis and tested positive for Mantoux test. However, none of them tested positive for AFB

\*Corresponding author: Lakshmi Krishnasamy, Department of Microbiology, Sree Balaji Medical College and Hospital, Bharath Institute of Higher Education and Research, Chennai, Tamil Nadu, India. [laksh45@gmail.com](mailto:laksh45@gmail.com)

Received: 14 September 2022 Accepted: 22 September 2022 Epub Ahead of Print: 09 January 2023 Published: 27 January 2023 DOI: 10.25259/JNRP\_13\_2022

This is an open-access article distributed under the terms of the Creative Commons Attribution-Non Commercial-Share Alike 4.0 License, which allows others to remix, transform, and build upon the work non-commercially, as long as the author is credited and the new creations are licensed under the identical terms. ©2023 Published by Scientific Scholar on behalf of Journal of Neurosciences in Rural Practice

**Table 1:** Details of the patients with calvarial tuberculosis.

S. No.	Age/sex	Presenting symptoms	On clinical examination	Laboratory findings	Radiological findings	Management
Patient No. 1	56/M	Swelling in the vertex, forehead with pain – 1 month, known diabetic	Swelling without inflammatory signs, mild tenderness	Raised ESR, Mantoux positive	Contrast-enhancing destructive lesion with thinning of both tables, epidural granulation [Figure 1]	Debridement and excision and ATT
Patient No. 2	80/F	Right parieto-occipital swelling with pus discharge	Fluctuant, non-tender abscess with pus discharge after attempted Tapping elsewhere.	Raised ESR, Mantoux positive	Enhancing epidural abscess with subgaleal extension destruction of bone [Figure 2]	Debridement and excision with ATT
Patient No. 3	35/M	Left frontoparietal swelling	Non-tender swelling	Raised ESR, Mantoux positive	Contrast-enhancing soft-tissue lesion with bone erosions	Debridement and excision and ATT
Patient No. 4	72/M	Diabetic, pulmonary tuberculosis, occipital pain, neck pain	Right 9,10,11,12 cranial nerve palsy, tenderness present, restricted neck movements	Raised ESR, Mantoux positive	Skull bone osteomyelitis involving occipital bone and condyle on right side; no instability	Debridement and ATT
Patient No. 5	50/M	Swelling left side forehead	Non-tender swelling	Raised ESR, Mantoux positive	Contrast-enhancing lytic lesion with abscess	Debridement and ATT
Patient No. 6	28/M	Left occipital swelling	Tenderness present, fluctuant	Raised ESR, Mantoux positive	Contrast-enhancing epidural abscess with granulation	Debridement and ATT
Patient No. 7	48/M	Right frontoparietal swelling	Non-tender swelling	Raised ESR, Mantoux positive	Epidural abscess with bone destruction	Debridement and ATT

ESR: Erythrocyte sedimentation rate, ATT: Antitubercular treatment

staining. Two out of four pus samples tested for GeneXpert were positive.

Chest X-ray was done in all the patients. One patient was found to have coexisting pulmonary tuberculosis. Antitubercular treatment (ATT) was started for all the patients and the patients were followed up for a minimum of 2 years.

## DISCUSSION

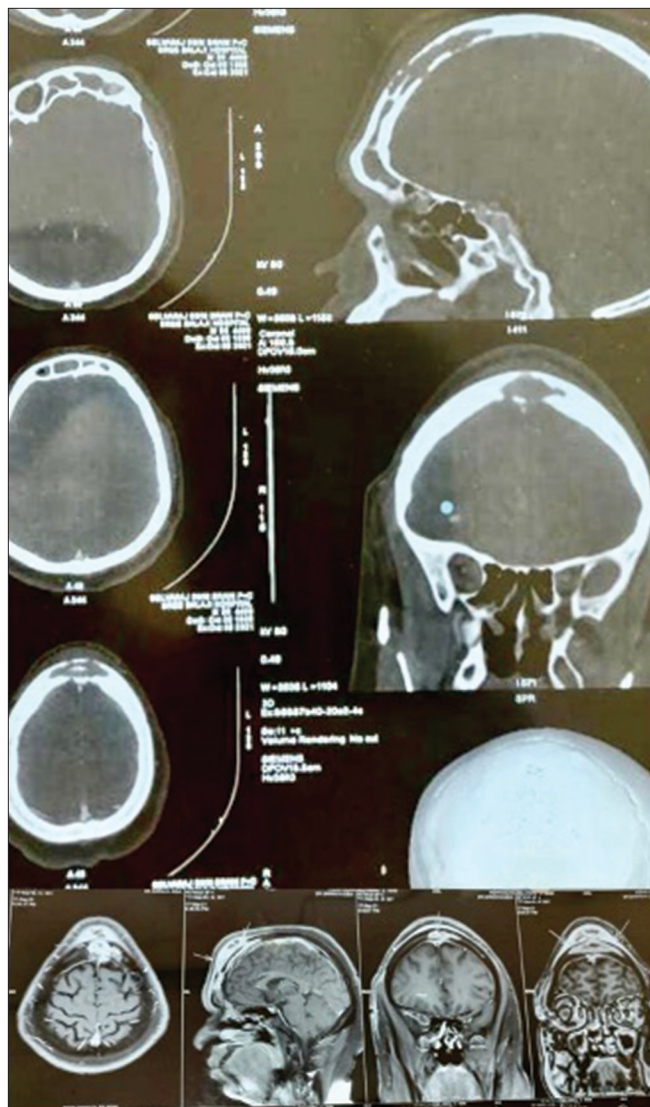
The first patient with calvarial tuberculosis was reported by Ried in 1842.<sup>[2]</sup> The set of patients in our study were >25 years of age, whereas another study conducted in Mumbai by Diyora *et al.* reported 11 patients diagnosed with calvarial tuberculosis in <25 years of age.<sup>[3]</sup> Although there is no sex predilection,<sup>[4]</sup> male predominance was observed in our study, similar to the study by Diyora *et al.*<sup>[3]</sup>

The primary focus is usually somewhere else in the body and the disease secondarily occurs from the unknown primary focus spreading through the hematogenous route. Lodgment of the tubercle bacilli in the diploic areas of skull bone from the extracalvarial focus through the hematogenous spread

is the important event in the pathogenesis of the disease. Surgery and trauma can also lead to direct inoculation of the tuberculous bacilli.<sup>[4,5]</sup> In our study, four patients had frontoparietal region involvement and three cases had involvement of occipital or parieto-occipital regions. The disease rarely affects the infants due to paucity of the cancellous bones in infant skull.<sup>[6]</sup>

Tuberculosis affecting the skull has been reported in 0.01% of patients infected with *Mycobacterium*.<sup>[7]</sup> As the skull bone is deficient with lymphatic supply, lymphatic spread from primary focus is very rare which explains why calvarial tuberculosis is a rare entity. Host immunity and the virulence of the bacilli are the precipitating factors for further development of the infection after the lodgment of the organism in the diploe-rich places.

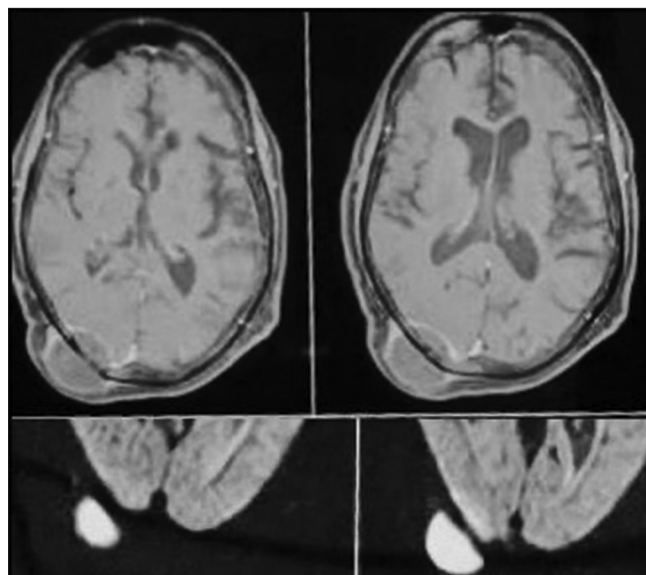
The pathogenesis of calvarial tuberculosis usually differs depending on the immune status of the individuals. If the patient's immunity is good, the process would be slow resulting in restricted evolution of the infection, whereas in immunocompromised patients, the disease would rapidly spread resulting in subgaleal or extradural collections.



**Figure 1:** (Patient 1); Contrast-enhancing lesion in between the two tables of bilateral frontal bones near the midline and vertex with erosions of the skull bone, subgaleal, and epidural deposits.

Isolated skull bone involvement is infrequent. The disease may present with scalp swelling, discharging sinuses, seizures, meningitis, headache, motor deficits, etc.

The common presentation of the skull tuberculosis is a discrete, round or oval, and solitary lesion in the frontoparietal bones with a minimal sclerosis around the lesion. Non-tender fluctuant swelling is the most common form of presentation in most of the cases. In our study, swelling in the scalp and discharging sinus were the common symptoms. Skin attachment and formation of sinus are the few other common modes of presentation. Few patients report with systemic manifestations such as weight loss and loss of appetite. Pain is another common presenting symptom. However, in our study, we found that the swelling



**Figure 2:** (Patient 2) Contrast T1W magnetic resonance imaging showing central necrotic pus with peripheral enhancement on either side of the right occipital bone; restriction noted in diffusion-weighted images.

in the scalp was non-tender in four patients and mild-to-moderate tenderness was found in the other three patients.

In our study, one patient had skull base tuberculosis with cranial nerve palsies. The patient presented with cranial nerve involvement, which was due to perineural involvement of the granulomatous lesion through the foramen in the skull base. We have not included patients who had cervical or craniovertebral junction tuberculosis in this study; we have also excluded those who had concomitant or contiguous involvement of skull base and cervical spine. Few patients diagnosed with calvarial tuberculosis were reported to have extradural lesion in few other studies.<sup>[8-10]</sup> In our study too, almost all cases had extradural disease although dura was inflamed and thickened in four cases. None of them had systemic illness or meningitis. ESR was elevated and Mantoux test was found to be positive in all the patients. Similar observation has been reported in the literature.<sup>[10]</sup>

The different presentations of calvarial tuberculosis in radiography are either circumscribed sclerotic/lytic lesions or diffuse tuberculosis affecting the cranium. Sclerosis is rare, if present, usually indicates secondary infection. Computed tomography scan assists in assessing the amount of destruction of bone, extent of intracranial involvement, degree of scalp swelling, etc. Magnetic resonance imaging is highly specific and visualizes the alterations in the meninges, ventricular wall, and parenchymal involvement. Identification of acid-fast bacilli in the specimen helps in the definitive diagnosis. However, AFB may not be demonstrable in few smears due to severe necrosis. In such cases, appropriate diagnosis can be made with radiological and circumstantial clinical evidence.

Accurate diagnosis, adequate antituberculous therapy, and appropriate surgical intervention are the mainstay in the management of the calvarial tuberculosis. Although a few studies suggest that antitubercular treatment is alone sufficient,<sup>[4]</sup> we concur with the opinion from studies suggesting surgical intervention in addition to ATT because the diseased bone might be the source of bacilli and removal by surgical excision<sup>[11,12]</sup> may be required to achieve a cure. Furthermore, debridement may facilitate the chemotherapeutic drugs to reach the infected bone easily and thereby reduce the chances of recurrence. In the present study, all the patients completed 1 year of ATT. The follow-up period ranged from 2 to 7 years. Adjuvant antibiotic therapy is warranted in case of secondary bacterial infections. Prognosis is usually good with proper management of cases. All the seven patients in our study responded well to treatment.

## CONCLUSION

The clinical presentations of calvarial tuberculosis may not be typical in all cases. The indication of systemic tuberculosis may not be found in every case. The radiological findings are usually supportive. Mantoux and ESR are helpful markers. Tissue diagnosis is the gold standard in confirming the identification of the cases. ATT is the major treatment modality. Surgical intervention is indicated in large or infected epidural collections. Combined treatment with antitubercular therapy and surgical excision is the preferred mode of management in most of the cases.

## Declaration of patient consent

The authors certify that they have obtained all appropriate patient consent.

## Financial support and sponsorship

Nil.

## Conflicts of interest

There are no conflicts of interest.

## REFERENCES

1. Unuvar E, Oguz F, Sadikoglu B, Sidal M, Ones U, Tetikkurt S. Calvarial tuberculosis. *J Paediatr Child Health* 1999;35:221-2.
2. Jadhav RN, Palande DA. Calvarial tuberculosis. *Neurosurgery* 1999;45:1345-9.
3. Diyora B, Kumar R, Modgi R, Sharma A. Calvarial tuberculosis: A report of eleven patients. *Neurol India* 2009;57:607-12.
4. LeRoux PD, Griffin GE, Marsh HT, Winn HR. Tuberculosis of the skull: A rare condition. Case report and review of literature. *Neurosurgery* 1990;26:851-5.
5. Biniwale SN, Rajshekhar V. Tuberculous osteomyelitis of bone flap following craniotomy for a glioma [letter]. *Neurol India* 2000;48:91-2.
6. Bhandari B, Mandowara SL, Harish J. Tuberculous osteomyelitis of skull. *Indian J Pediatr* 1981;48:113-5.
7. Strauss DC. Tuberculosis of flat bones of the vault of the skull. *Surg Gynecol Obstet* 1933;57:384-98.
8. Mukherjee KK, Kaushik R, Nada R, Khosla VK, Khandelwal N, Kak VK. Calvarial tuberculosis. *Surg Neurol* 2002;57:195-203.
9. Shahat AH, Rahman NU, Obaideen AM, Ahmed I, Zahman Au A. Cranial-epidural tuberculosis presenting as a scalp swelling. *Surg Neurol* 2004;61:464-7.
10. Awasthy N, Chand K, Singh A. Calvarial tuberculosis. Review of six cases. *Ann Indian Acad Neurol* 2006;9:227-9.
11. Mohanty S, Rao CJ, Mukherjee KC. Tuberculosis of the skull. *Int Surg* 1981;66:81-3.
12. Ip M, Tsui E, Wong KL, Jones B, Pung CF, Ngan H. Disseminated skeletal tuberculosis with skull involvement. *Tuberc Lung Dis* 1993;74:211-4.

**How to cite this article:** Rengarajan S, Krishnasamy L. Calvarial tuberculosis – A report of seven cases from a tertiary care hospital. *J Neurosci Rural Pract* 2023;14:123-6.