

Review Article

Chromosome Xp22.3 deletion syndrome with X-linked ichthyosis, Kallmann syndrome, short stature, generalized epilepsy, hearing loss, attention deficit hyperactivity disorder, and intellectual disability – A rare report with review of literature

Pradeep Kumar Gunasekaran¹, Lokesh Saini¹, Tanuja Rajial¹ , Sujatha Manjunathan¹, Veena Laxmi¹, Rahul Gupta¹, Ashna Kumar¹, Arun Sree Parameswaran¹, Achanya Palayullakandi², Anil Budania³, Kuldeep Singh¹ 

¹Department of Pediatrics, All India Institute of Medical Sciences, Jodhpur, Rajasthan, ²Department of Pediatrics, All India Institute of Medical Sciences, Rishikesh, Uttarakhand, ³Department of Dermatology Venereology and Leprosy, All India Institute of Medical Sciences, Jodhpur, Rajasthan, India.

ABSTRACT

Chromosome Xp22.3 deletion syndrome is a very rare contiguous gene deletion syndrome with variable phenotype due to the deletion of genes from the distal short arm of the X chromosome (Xp), including the short-stature homeobox (*SHOX*), anosmin-1 (*ANOS1*), arylsulfatase (*ARSL*), neuroligin-4 (*NLGN4*), and steroid sulfatase (*STS*) genes. We have reviewed the available literature on the chromosome Xp22.3 deletion syndrome. A 10-year-old boy presented with global developmental delay, generalized epilepsy, decreased hearing, and hyperactivity. He had no significant family history. Examination revealed microcephaly, short stature, and dry and scaly skin lesions on the trunk. He had thick arched eyebrows, a depressed nasal bridge, a long philtrum, high arched palate, retrognathia, brachytelephalangy, brachymetatarsia, and mild scoliosis. Brainstem-evoked response audiometry testing revealed moderate hearing loss. Magnetic resonance imaging showed cerebellar tonsillar ectopia. Clinical exome sequencing revealed a likely pathogenic contiguous deletion (~8.10 Mb) spanning genomic location chrX:g.(_630898)_ (8732037_)del encompassing *ANOS1*, *ARSL*, *NLGN4X*, *SHOX*, and *STS* genes. We have reviewed the available literature for reported associations of Chromosome Xp22.3 deletion syndrome and report a novel association of X-linked ichthyosis, Kallmann syndrome, global developmental delay, short stature, bilateral hearing loss, generalized epilepsy, attention deficit hyperactivity disorder, and intellectual disability.

Keywords: Chromosome Xp22.3 deletion syndrome, X-linked ichthyosis, Kallmann syndrome, Short stature, Generalized epilepsy

INTRODUCTION

Chromosome Xp22.3 deletion syndrome is a very rare contiguous gene deletion syndrome with variable phenotype, depending on the large terminal or interstitial codeletions of adjacent genes that are physically clustered. This contiguous gene syndrome is due to the deletion of genes from the distal short arm of the X chromosome (Xp), including the *short-stature homeobox* (*SHOX*), *anosmin-1* (*ANOS1*), arylsulfatase (*ARSL*), neuroligin-4 (*NLGN4*), and steroid sulfatase (*STS*) genes.^[1] This syndrome is characterized by X-linked ichthyosis (XLI), Kallmann syndrome (KS), short stature, generalized epilepsy, neurodevelopmental disorders including autism spectrum disorder (ASD), attention deficit hyperactivity disorder (ADHD), and intellectual disability (ID), sensorineural hearing loss, strabismus, and bony deformities including chondrodysplasia punctata (CDP), obesity,

and ocular albinism.^[1-3] The other dysmorphism features reported are frontal bossing, hypertelorism, depressed nasal bridge, high-arched palate, retrognathia, and flat occiput.^[4,5] Based on the deletion lengths, the clinical phenotypes occur independently from each other or in various combinations as a contiguous gene syndrome.^[6] Only about 34 cases have been reported in the literature. Here, we report a case of Xp22.3 deletion syndrome (8.1 Mb contiguous deletion), including *ANOS1*, *ARSL*, *NLGN4X*, *SHOX*, and *STS* genes, along with a review of available literature [Table 1].

CASE PRESENTATION

A 10-year-old boy presented with global developmental delay, decreased hearing since birth, and hyperactivity. He also had a history of generalized tonic-clonic seizures since five years of age, with 1–2 episodes/year. He was first

*Corresponding author: Lokesh Saini, Department of Pediatrics, All India Institute of Medical Sciences, Jodhpur, Rajasthan, India. drlokeshsaini@gmail.com

Received: 25 August 2023 Accepted: 06 May 2024 Epub ahead of print: 13 July 2024 Published: XXXX DOI: 10.25259/JNRP_467_2023

This is an open-access article distributed under the terms of the Creative Commons Attribution-Non Commercial-Share Alike 4.0 License, which allows others to remix, transform, and build upon the work non-commercially, as long as the author is credited and the new creations are licensed under the identical terms. ©2024 Published by Scientific Scholar on behalf of Journal of Neurosciences in Rural Practice

born to third-degree consanguineously married parents. The antenatal and perinatal periods were unremarkable. There was no significant family history. On examination, he had a height of 116 cm (−3.5Z, stunting), a weight of 25.2 Kg (−1.3Z), body mass index of 18.7 kg/m², and a head circumference of 53 cm. The upper-to-lower segment ratio (US: LS) was 0.93. The mid-parental height was 159 cm. He had coarse facies with thick arched eyebrows, long philtrum, retrognathia, depressed nasal bridge, high arched palate, brachytelephalangy, brachymetatarsia, and mild scoliosis [Figure 1a-c]. He had dry, scaly skin lesions over the axilla, lateral side of the chest, and abdomen, suggestive of ichthyosis [Figure 1d-f]. On genitalia examination, he had a stretched penile length of 3.5 cm and a testicular volume of <2cc (Tanner staging – G1, no axillary and pubic hair). The rest of the systemic examination was normal, with no organomegaly. Fundus examination was normal. Based on the clinical presentation, the possibilities of multiple sulfatase deficiency and Sjogren–Larsson syndrome were considered.

He had a normal hemogram, renal, liver, and thyroid function tests, and a normal bone metabolic profile. He had normal cortisol levels (9.92 [3.09–16.66] µg/dL), low levels of testosterone (7.0 [241–827] ng/dL), luteinizing hormone (0.21 [2.8–6.8] mIU/mL), prolactin (50.4 [87–392] mIU/L), and insulin growth factor 1 (9.05 [131–490] ng/mL). The testing for smell with common odors revealed anosmia in the index child. The urinary testing for mucopolysaccharides was negative. Ultrasonogram study of the abdomen and pelvis was normal. The 2D echocardiography study was normal. The skeletal survey revealed abnormal development of distal phalanges of bilateral 1st – 4th fingers, coxa valga, and mild concavity with enlarged intervertebral discs in the lower thoracic and lumbar regions. Magnetic resonance imaging showed a normal pituitary gland, crowded posterior fossa with effacement of the fourth ventricle, and cerebellar tonsillar ectopia. Brain-evoked auditory response testing revealed bilateral moderate (60 dB) hearing loss. Clinical exome sequencing revealed a contiguous deletion of size (~8.10 Mb), spanning genomic location chrX:g.(_630898)_ (8732037_)del encompassing multiple genes including *ANOS1*, *ARSL*, *NLGN4X*, *SHOX*, *STS* was detected, suggestive of chromosome Xp22.3 deletion syndrome. The child is currently on a multidisciplinary follow-up.

LITERATURE SEARCH

A literature review was performed from the year 2023 to the oldest available report in English on Chromosome Xp22.3 deletion syndrome from the PubMed/MEDLINE, Google Scholar, and SCOPUS databases. All articles describing Chromosome Xp22.3 deletion syndrome were identified, and duplicates were removed. A total of 34 cases (excluding

the index child) have been described in the literature and are summarized in Table 2.

DISCUSSION

The genetic analysis of the index child revealed a contiguous deletion of size (~8.10 Mb) in terminal Xp22.3 region encompassing multiple genes, including *ANOS1* (*KAL1*), *ARSL*, *NLGN4X*, *SHOX*, and *STS*, suggestive of chromosome Xp22.3 deletion syndrome [Figure 2]. This deletion was classified as a “likely pathogenic” copy number variation based on the American College of Medical Genetics guidelines.^[7] The index child’s distinctive features were ichthyosis, global developmental delay, short stature, bilateral hearing loss, and hyperactivity. In the index child, along with signs of hypogonadism and anosmia, KS was diagnosed.

The deletions of the Xp22.31 – p22.33 region result in contiguous gene syndromes with various phenotypical combinations of XLI, KS, short stature, CDP, developmental delay, ASD, ID, strabismus, obesity, ocular albinism, and bilateral hearing loss [Table 1].^[1,8-10] The XLI (MIM#308100) is characterized by dry, dark-colored scales over the trunk and limbs, which is due to deletions of *STS* gene.^[11] The absence of *STS* causes the accumulation of cholesterol sulfate in the stratum corneum, resulting in impaired skin permeability and hyperkeratosis.^[12] The *ANOS1* gene is located near the *STS* gene near the Xp22.3 locus, and the deletion of the *ANOS1* gene causes X-linked KS. The *ANOS1* gene encodes the anosmin-1 protein, which is present in the cerebral cortex and olfactory system. Anosmin-1 also mediates the adhesion and the axonal migration of gonadotrophin-releasing hormone (GnRH) neurons.^[10] KS (MIM#308700) is due to deficiency of GnRH and hypoplasia of olfactory bulbs and is characterized by hypogonadotropic hypogonadism, anosmia/hyposmia, and other features may include cleft lip/palate, hearing loss, and unilateral renal agenesis.^[10]

SHOX on the Xp gene is a homeobox gene involved in skeletal development and maturation. *SHOX*-related disorders have a highly variable phenotypic spectrum ranging from short stature to Leri-Weill dyschondrosteosis, which consists of a triad of mesomelia, short stature, and Madelung deformity (MD) (MIM#300582).^[13] *ARSL* gene encodes *ARSL*, a member of the sulfatase family that is essential for the composition of bone and cartilage matrix.^[14] The deletion of these genes results in short stature and X-linked chondrodysplasia punctata-1 (CDPX1). CDPX1 (MIM#302950) is characterized by brachytelephalangy – short distal phalanges, CDP – stippled epiphyses, nasomaxillary hypoplasia, short stature, hearing loss, vertebral abnormalities including dysplastic and hypoplastic vertebrae, developmental delay, ID, and cataracts.^[14]

NLGN4X gene encodes the cell surface proteins of neurons. They are involved in forming and remodeling the synapses

Table 1: Genes of interest in Xp22.3 region and its phenotypes.

S. No	Location	Genes	MIM*	Phenotype	Phenotype MIM#
1.	Xp22.31	<i>ANOS1</i>	300836	Kallmann syndrome	308700
2.	Xp22.31	<i>STS</i>	300747	Ichthyosis	308100
3.	Xp22.32	<i>NLGN4X</i>	300427	ASD, ID	300495
4.	Xp22.33	<i>ARSL</i>	300180	Chondrodysplasia punctata, Short stature	302950
5.	Xp22.33	<i>SHOX</i>	312865	Short stature homeobox	300582

ASD: Autism spectrum disorder; ID: Intellectual disability; LWD: Leri-Weill dyschondrosteosis; MD: Madelung deformity; MIM: Online Mendelian inheritance in man.

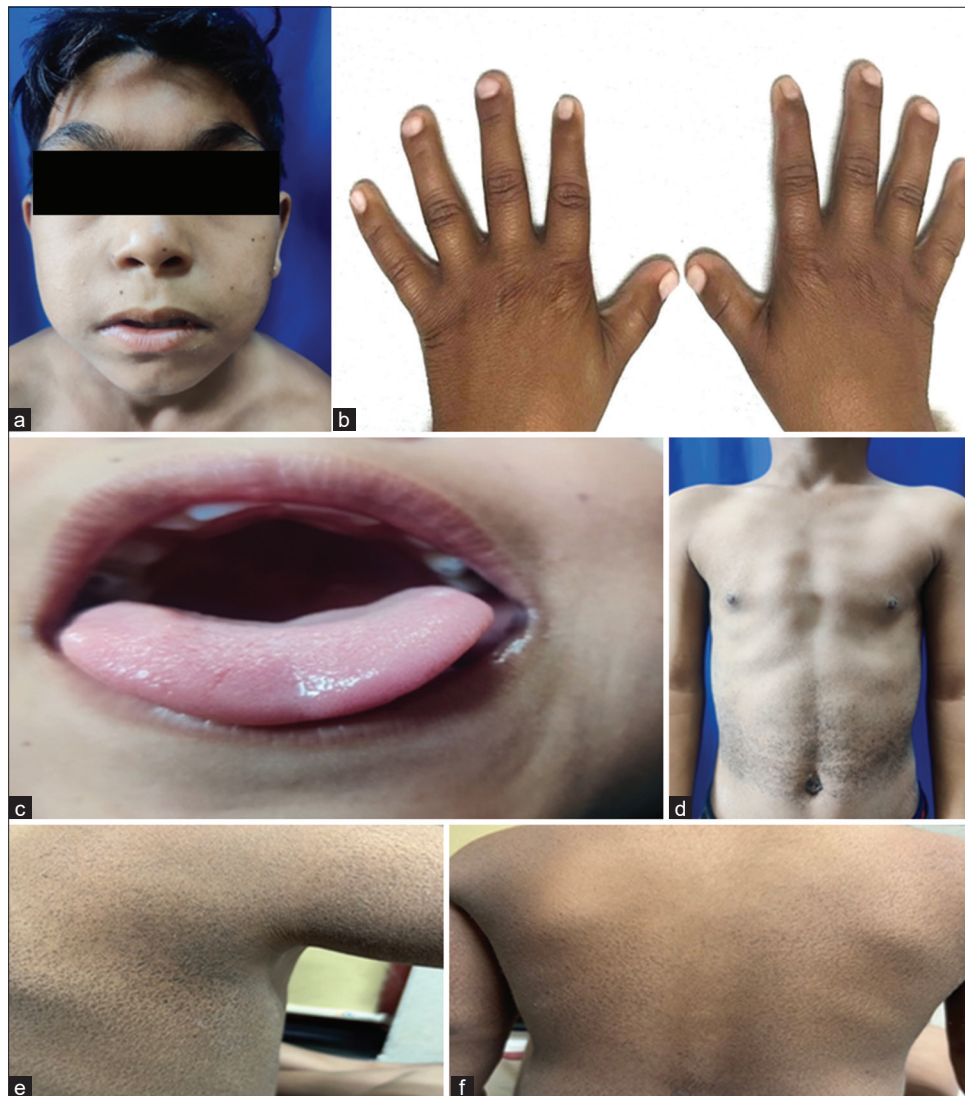


Figure 1: Clinical features in the Index Child. (a-f) shows dysmorphic features and Ichthyosis. (d) shows pectus excavatum. (a) Facial dysmorphism, (b) brachytelephalangy, (c) high-arched palate, (d) ichthyosis over the abdomen, (e) ichthyosis over the axilla, (f) ichthyosis over the back.

in the central nervous system. The deletion of *NLGN4X* causes X-linked ASD (MIM#300495) and X-linked ID

(MIM#300495).^[15] The deletion of other genes, including variably charged protein X-A (*VCX-A*), can also result in

Table 2: Summary of Xp22.3 deletions and phenotype associations reported in literature.

S. No	Author/year	Deletions	Age	Sex	Ich	SS	KS	CDP	MD	LWD	Epilepsy	ASD	ADHD	ID	OA	HL
1.	Ballabio <i>et al.</i> 1988 ^[20]	Xp22.3	6y	M	+	+	-	+	-	-	+	-	-	+	-	-
2.	Bick <i>et al.</i> 1989 ^[21]	Xp22.31	6y	M	+	-	-	-	-	-	-	-	-	+	-	-
3.	Meindl <i>et al.</i> 1993 ^[22]	Xp22.3 9.9 Mb	2.5m	M	+	-	+	+	-	-	-	-	-	+	-	-
4.	Schwinger <i>et al.</i> 1996 ^[23]	Xp22.32	9y	M	+	+	+	+	-	-	-	-	-	+	-	-
5.	Spranger <i>et al.</i> 1999 ^[18]	Xp22.3	10y	F	-	+	-	-	-	-	-	-	-	-	-	-
6.	Spranger <i>et al.</i> 1999 ^[18]	Xp22.3	5y	M	-	+	-	-	+	+	+	-	+	-	-	+
7.	Gohlke <i>et al.</i> 2000 ^[24]	Xp22.3	8y	M*	+	-	+	-	-	-	-	-	-	+	-	-
8.	Doherty <i>et al.</i> 2003 ^[11]	Xp22.3	8y	M*	+	+	+	-	-	-	+	-	-	+	-	-
9.	Doherty <i>et al.</i> 2003 ^[11]	Xp22.3	24y	M	+	+	-	-	-	+	+	-	-	+	-	-
10.	Boycott <i>et al.</i> 2003 ^[19]	Xp22.3 6 Mb	22y	M	+	+	-	-	-	+	+	-	+	-	-	-
11.	Boycott <i>et al.</i> 2003 ^[19]	Xp22.3 6 Mb	24y	M	-	-	-	-	-	-	+	-	+	-	-	-
12.	Lonardo <i>et al.</i> 2007 ^[9]	Xp22.3 5.5 Mb	23y	M	-	+	-	-	+	-	-	-	+	-	-	-
13.	Lonardo <i>et al.</i> 2007 ^[9]	Xp22.3 5.5 Mb	13y	M	+	+	-	+	-	-	-	-	+	-	-	+
14.	Macarov <i>et al.</i> 2007 ^[15]	Xp22.3	2y	M	+	-	+	-	-	-	-	-	-	-	-	-
15.	Macarov <i>et al.</i> 2007 ^[15]	Xp22.3	22y	M	+	-	+	-	-	-	-	-	-	-	-	-
16.	Macarov <i>et al.</i> 2007 ^[15]	Xp22.3	48y	M	+	-	+	-	-	-	-	-	-	-	-	-
17.	Melichar <i>et al.</i> 2007 ^[25]	Xp22.31 9.6 Mb	1m	M	+	-	An	+	-	-	-	-	-	-	+	+
18.	Puusepp <i>et al.</i> 2008 ^[26]	Xp22.3	16y	F	-	+	-	-	+	-	+	-	+	-	-	-
19.	Mochel <i>et al.</i> 2008 ^[17]	Xp22.3 3.7 Mb	17y	M	+	+	+	-	-	-	-	-	-	-	-	-
20.	Van Steensel <i>et al.</i> 2008 ^[4]	Xp22.3 8.4 Mb	21y	M	+	+	+	-	-	-	+	-	-	+	-	-
21.	Bukvic <i>et al.</i> 2010 ^[8]	Xp23.33 7.7 Mb	3y3m	M	+	-	-	-	+	-	-	-	+	-	-	-
22.	Palka-Bayard-de-Volo <i>et al.</i> 2012 ^[27]	Xp22.3 6.8 Mb	1y8m	F	-	-	-	-	-	-	-	-	-	-	-	-
23.	Palka-Bayard-de-Volo <i>et al.</i> 2012 ^[27]	Xp22.3 6.8 Mb	11y	F	-	+	-	-	-	-	-	-	-	+	-	-
24.	Khelifa <i>et al.</i> 2013 ^[5]	Xp22.3 2 Mb	14y	M	+	-	-	-	-	-	+	-	-	+	-	-
25.	Xu <i>et al.</i> 2015 ^[28]	Xp22.3 1.6 Mb	-	M	+	-	+	-	-	-	-	-	-	-	-	-
26.	Vrečar <i>et al.</i> 2015 ^[29]	Xp22.33 3 Kb	-	M	+	-	+	-	-	-	-	-	-	-	-	-
27.	Berges-Raso <i>et al.</i> 2017 ^[30]	Xp22.3 4.7 Mb	9y	M	-	-	-	+	-	-	-	-	-	-	-	+
28.	Berges-Raso <i>et al.</i> 2017 ^[30]	Xp22.3 4.7 Mb	39y	M	+	-	+	-	-	-	-	-	-	-	-	-
29.	Amasdl <i>et al.</i> 2017 ^[2]	Xp22.33 3.1Mb	6y	M	-	+	-	-	-	-	-	-	-	-	-	+
30.	Nagai <i>et al.</i> 2017 ^[16]	Xp22.31 2.7 Mb	22y	M	+	+	+	-	-	-	-	-	-	-	-	+
31.	Saitt <i>et al.</i> 2020 ^[3]	Xp22.33 8.3 Mb	6m	M	+	-	+	-	-	-	-	-	-	-	-	-
32.	Saitt <i>et al.</i> 2020 ^[3]	Xp22.33 8.3 Mb	20y	M	+	+	+	-	-	-	-	-	-	+	-	-
33.	Ma <i>et al.</i> 2020 ^[10]	Xp22.31 3.9 Mb	14y	M	+	-	+	-	-	-	-	-	-	-	-	-
34.	Index Study 2023	Xp22.3 5.8 Mb	19y	M	+	-	+	-	-	-	-	-	-	-	-	-
35.	Index Study 2023	Xp22.32 8.1 Mb	10y	M	+	+	+	-	-	-	+	-	+	+	-	+

An: Anticipated, F: Female, M: Male, m: months, y: years, * Monozygotic twins. ASD: Autism spectrum disorder, ADHD: Attention deficit hyperactivity disorder, CDP: Chondrodysplasia punctata, HL: Hearing loss, Ich: Ichthyosis, ID: Intellectual disability, KS: Kallmann syndrome, LWD: Leri-Weill dyschondrosteosis, MD: Madelung deformity, OA: Ocular albinism, SS: Short stature

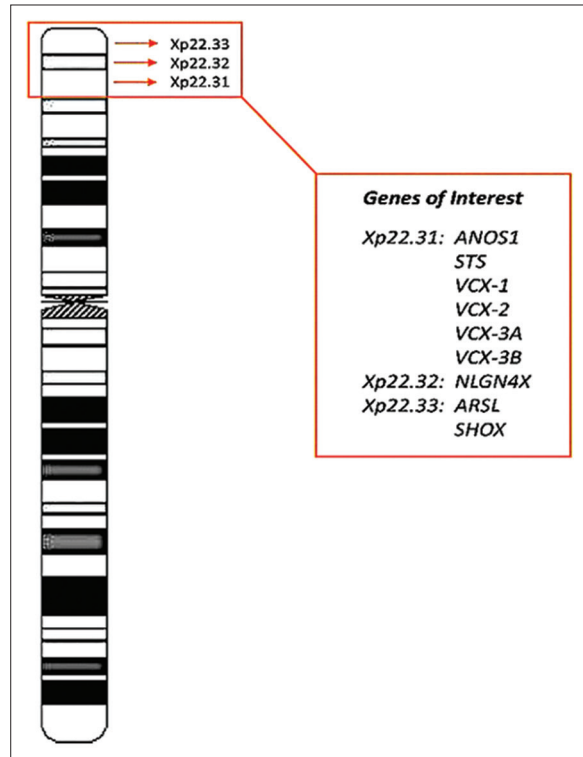


Figure 2: Chromosome Xp22.3 region with associated significant Genes. G-banding Ideogram of X chromosome (800 bps resolution) showing Xp22.3 region with the Genes of Interest.

X-linked ID. The deletions of *NLGN4X* and *VCX-A* can cause variable phenotypes, including normal intellect.^[5,15-17] Recently, in these associated contiguous gene syndromes involving Xp22.3, ADHD has been reported.^[1,9,18,19]

In Xp22.3 microdeletions, cortical heterotopias, hypoplasia of corpus callosum, mild enlargement of sella turcica, olfactory bulb dysplasia (KS patients), and Dandy-Walker malformation have been reported.^[4,8,10] Similarly, cerebellar tonsillar ectopia was noted in the index child, which has not been reported in the literature. The available literature on contiguous Xp22.3 deletion was reviewed and summarized in Table 2.

Limitations

The literature search included articles published only in the English language.

CONCLUSION

Contiguous gene syndromes exhibit complex disease phenotypes stemming from the microdeletion of multiple adjacent contiguous genes. These phenotypical associations serve as valuable indicators for the diagnosis, underscoring the critical role of recognizing them in establishing

diagnoses and multimodal management planning for these patients.

Ethical approval

The Institutional Review Board approval is not required.

Declaration of patient consent

The authors certify that they have obtained all appropriate patient consent.

Financial support and sponsorship

Nil.

Conflicts of interest

There are no conflicts of interest.

Use of artificial intelligence (AI)-assisted technology for manuscript preparation

The authors confirm that there was no use of artificial intelligence (AI)-assisted technology for assisting in the writing or editing of the manuscript and no images were manipulated using AI.

REFERENCES

1. Doherty MJ, Glass IA, Bennett CL, Cotter PD, Watson NF, Mitchell AL, *et al.* An Xp; Yq translocation causing a novel contiguous gene syndrome in brothers with generalized epilepsy, ichthyosis, and attention deficits. *Epilepsia* 2003;44:1529-35.
2. Amasdl S, Smaili W, Natiq A, Hassani A, Sbiti A, Agadr A, *et al.* Familial X/Y translocation encompassing ARSE in two moroccan siblings with sensorineural deafness. *Cytogenet Genome Res* 2017;153:66-72.
3. Sait H, Srivastava P, Dabadghao P, Phadke SR. Kallmann syndrome and X-linked ichthyosis caused by translocation between chromosomes X and Y: A case report. *J Reprod Infertil* 2021;22:302-6.
4. Van Steensel MA, Vreeburg M, Engelen J, Ghesquiere S, Stegmann AP, Herbergs J, *et al.* Contiguous gene syndrome due to a maternally inherited 8.41 Mb distal deletion of chromosome band Xp22.3 in a boy with short stature, ichthyosis, epilepsy, mental retardation, cerebral cortical heterotopias and Dandy-Walker malformation. *Am J Med Genet A* 2008;146A:2944-9.
5. Ben Khelifa H, Soyah N, Ben-Abdallah-Bouhjar I, Gritly R, Sanlaville D, Elghezal H, *et al.* Xp22.3 interstitial deletion: A recognizable chromosomal abnormality encompassing VCX3A and STS genes in a patient with X-linked ichthyosis and mental retardation. *Gene* 2013;527:578-83.
6. Ballabio A, Andria G. Deletions and translocations involving the distal short arm of the human X chromosome: Review and hypotheses. *Hum Mol Genet* 1992;1:221-7.

7. Richards S, Aziz N, Bale S, Bick D, Das S, Gastier-Foster J, *et al.* Standards and guidelines for the interpretation of sequence variants: A joint consensus recommendation of the American College of Medical Genetics and Genomics and the Association for Molecular Pathology. *Genet Med* 2015;17:405-24.
8. Bukvic N, Delli Carri V, Di Cosola ML, Pustorino G, Cesarano C, Chetta M, *et al.* Familial X;Y translocation with distinct phenotypic consequences: Characterization using FISH and array CGH. *Am J Med Genet A* 2010;152A:1730-4.
9. Lonardo F, Parenti G, Luquetti DV, Annunziata I, Monica MD, Perone L, *et al.* Contiguous gene syndrome due to an interstitial deletion in Xp22.3 in a boy with ichthyosis, chondrodysplasia punctata, mental retardation and ADHD. *Eur J Med Genet* 2007;50:301-8.
10. Ma W, Mao J, Wang X, Duan L, Song Y, Lian X, *et al.* Novel microdeletion in the X chromosome leads to Kallmann syndrome, ichthyosis, obesity, and strabismus. *Front Genet* 2020;11:596.
11. Takeichi T, Akiyama M. Inherited ichthyosis: Non-syndromic forms. *J Dermatol* 2016;43:242-51.
12. Crane JS, Paller AS. X-Linked ichthyosis. In: *StatPearls*. Treasure Island, FL: StatPearls Publishing; 2023. Available from: <https://www.ncbi.nlm.nih.gov/books/NBK448149> [Last accessed on 2024 May 05].
13. Binder G, Rappold GA. SHOX deficiency disorders. In: Adam MP, Feldman F, Mirzaa GM, Pagon RA, Wallace SE, Bean LJ, *et al.*, editors. *GeneReviews*[®]. Seattle, WA: University of Washington, Seattle; 1993-2023. Available from: <https://www.ncbi.nlm.nih.gov/books/NBK1215> [Last accessed on 2024 May 05].
14. Braverman NE, Bober MB, Brunetti-Pierri N, Suchy SF. Chondrodysplasia punctata 1, X-linked. In: Braverman NE, Bober MB, Brunetti-Pierri N, Adam MP, Mirzaa GM, Pagon RA, *et al.*, editors. *GeneReviews*[®]. Seattle, WA: University of Washington, Seattle; 1993-2023. Available from: <https://www.ncbi.nlm.nih.gov/books/NBK1544> [Last accessed on 2024 May 05].
15. Macarov M, Zeigler M, Newman JP, Strich D, Sury V, Tennenbaum A, *et al.* Deletions of VCX-A and NLGN4: A variable phenotype including normal intellect. *J Intellect Disabil Res* 2007;51(Pt 5):329-33.
16. Nagai K, Shima H, Kamimura M, Kanno J, Suzuki E, Ishiguro A, *et al.* Xp22.31 microdeletion due to microhomology-mediated break-induced replication in a boy with contiguous gene deletion syndrome. *Cytogenet Genome Res* 2017;151:1-4.
17. Mochel F, Missirian C, Reynaud R, Moncla A. Normal intelligence and social interactions in a male patient despite the deletion of NLGN4X and the VCX genes. *Eur J Med Genet* 2008;51:68-73.
18. Spranger S, Schiller S, Jauch A, Wolff K, Rauterberg-Ruland I, Hager D, *et al.* Léry-Weill syndrome as part of a contiguous gene syndrome at Xp22.3. *Am J Med Genet* 1999;83:367-71.
19. Boycott KM, Parslow MI, Ross JL, Miller IP, Bech-Hansen NT, MacLeod PM. A familial contiguous gene deletion syndrome at Xp22.3 characterized by severe learning disabilities and ADHD. *Am J Med Genet A* 2003;122A:139-47.
20. Ballabio A, Parenti G, Carrozzo R, Coppa G, Felici L, Migliori V, *et al.* X/Y translocation in a family with X-linked ichthyosis, chondrodysplasia punctata, and mental retardation: DNA analysis reveals deletion of the steroid sulphatase gene and translocation of its Y pseudogene. *Clin Genet* 1988;34:31-7.
21. Bick D, Curry CJ, McGill JR, Schorderet DF, Bux RC, Moore CM. Male infant with ichthyosis, Kallmann syndrome, chondrodysplasia punctata, and an Xp chromosome deletion. *Am J Med Genet* 1989;33:100-7.
22. Meindl A, Hosenfeld D, Bruckl W, Schuffenhauer S, Jenderny J, Bacskulin A, *et al.* Analysis of a terminal Xp22.3 deletion in a patient with six monogenic disorders: Implications for the mapping of X linked ocular albinism. *J Med Genet* 1993;30:838-42.
23. Schwinger E, Kirschstein M, Greiwe M, Konermann T, Orth U, Gal A. Short stature in a mother and daughter with terminal deletion of Xp22.3. *Am J Med Genet* 1996;63:239-42.
24. Gohlke BC, Haug K, Fukami M, Friedl W, Noeker M, Rappold GA, *et al.* Interstitial deletion in Xp22.3 is associated with X linked ichthyosis, mental retardation, and epilepsy. *J Med Genet* 2000;37:600-2.
25. Melichar VO, Guth S, Hellebrand H, Meindl A, von der Hardt K, Kraus C, *et al.* A male infant with a 9.6 Mb terminal Xp deletion including the OA1 locus: Limit of viability of Xp deletions in males. *Am J Med Genet A* 2007;143A:135-41.
26. Puusepp H, Zordania R, Paal M, Bartsch O, Öunap K. Girl with partial Turner syndrome and absence epilepsy. *Pediatr Neurol* 2008;38:289-92.
27. Palka-Bayard-de-Volo C, De Marco S, Chiavaroli V, Alfonsi M, Calabrese G, Chiarelli F, *et al.* Array-CGH characterization of a *de novo* t(X;Y)(p22;q11) in a female with short stature and mental retardation. *Gene* 2012;504:107-10.
28. Xu H, Li Z, Wang T, Wang S, Liu J, Wang DW. Novel homozygous deletion of segmental KAL1 and entire STS cause Kallmann syndrome and X-linked ichthyosis in a Chinese family. *Andrologia* 2015;47:1160-5.
29. Vrečar I, Rudolf G, Peterlin B, Lovrecic L. Brachytelephalangic chondrodysplasia punctata caused by new small hemizygous deletion in a boy presenting with hearing loss. *Mol Cytogenet* 2015;8:83.
30. Berges-Raso I, Giménez-Palop O, Gabau E, Capel I, Caixàs A, Rigla M. Kallmann syndrome and ichthyosis: A case of contiguous gene deletion syndrome. *Endocrinol Diabetes Metab Case Rep* 2017;2017:EDM170083.

How to cite this article: Gunasekaran P, Saini L, Rajial T, Manjunathan S, Laxmi V, Gupta R, *et al.* Chromosome Xp22.3 deletion syndrome with X-linked ichthyosis, Kallmann syndrome, short stature, generalized epilepsy, hearing loss, attention deficit hyperactivity disorder, and intellectual disability – A rare report with review of literature. *J Neurosci Rural Pract.* doi: 10.25259/JNRP_467_2023