

Letter to Editor

Spike wave complexes riding T-waves in generalized and focal pattern in two patients with hepatic encephalopathy

Roshan Koul¹, Satyendra Kumar², Rakhi Maiwall³

Departments of ¹Neurology, ²Neurophysiology and ³Hepatology, ILBS, New Delhi, India.

Dear Editor,

Triphasic waves (T-waves) as the name suggests have 3 phases/waves. A high amplitude positive wave preceded and followed by slow negative phases.^[1] The T-waves are usually periodic, 1.5–2Hz, with a fronto-occipital time lag.^[2] Origin of T-waves is not clear. Several locations in the brain such as frontal lobes, cingulate gyrus, and thalamus have been thought to be the places of their origin.^[2] T-waves are not pathognomonic of any disease, though thought to be so when found 1st time in liver disease.^[3] Several metabolic, toxic, and structural lesions of the brain cause T-waves.^[2] Even white matter disease has been advocated as the origin of the T-waves.^[4] Recently, T-waves were reported in a child with autoimmune encephalitis.^[5] There are occasions when a patient with metabolic encephalopathy develops seizures or in a reverse situation a patient with genetic epilepsy which develops encephalopathy.^[6] It is easy to differentiate seizure discharges (spike waves/complexes) from T-waves when a patient is purely epileptic and has hepatic encephalopathy (HE). However, difficulties arise when a HE patient develops seizures and one finds T-waves and spike wave complexes (SWCs) in the patient. Although there are certain differentiating features between seizures and T-waves, at times, it is difficult to differentiate the two when both coexist and particularly override each other. We are reporting two patients of HE, who developed SWCs and T-waves, former overriding the latter. One had generalized SWCs and another focal SWCs. These complexes were riding the T-waves in both. In 3 years' time, about 2000 EEGs were performed in patients with HE in the intensive care setting. Most of the patients were intubated and on propofol, fentanyl. We report this entity due to its rarity. Over 4 years period (October 2018–September 2022), around 2000 EEGs were done in ICU patients with HE. Only two such EEGs were seen.

The two patients had severe HE and were intubated. They were on propofol and fentanyl. EEG revealed SWCs in them.

They were given loading levetiracetam and midazolam for seizures. Both patients did not survive.

Case 1. A 32-years-old male with chronic liver disease due to ethanol had been admitted with HE. In the intensive care unit, he developed focal seizures of the right side of body. He had history of focal seizures in past and was on levetiracetam since 2016. His CT brain had an old left temporal encephalomalacia. He did not survive the current episode of encephalopathy. EEG revealed focal epileptic discharges over left temporal region at the same time riding T-waves [Figure 1]. Another EEG after improvement in encephalopathy showed no T-waves, but focal seizures persisted [Figure 2]. The patient did not survive.

Case 2. A 50-year-old man with ethanol related chronic liver disease was admitted with HE. His EEG revealed generalized periodic discharges of T-waves superimposed with seizure discharges [Figure 3]. This patient also expired due to the liver disease. He had no brain imaging.

In this report, we are highlighting how to differentiate the SWCs (seizures) from T-waves when both coexist. There has always been doubt about the origin of T-waves.^[2] This finding also suggests that origin of seizure discharges and T-waves may be the same, depending on the underlying brain pathology. T-waves in encephalopathy have three phases and may resemble generalized SWCs which also have three phases.^[2] It is difficult to compare the two in such conditions.

There are differences in complex duration and waveform when morphology of generalized spike waves (GSWCs) is compared with T-waves in a patient with seizures and encephalopathy. GSWCs have higher frequency 1st, 2nd and 3rd phases. Phase 2 slope is steeper and brief after-going slow waves. GSWCs are approximately 0.12 s in duration and seen maximal at F3–F4.^[6] On the other hand, T-waves have higher voltage phases 2 and

*Corresponding author: Roshan Koul, Department of Neurology, ILBS, New Delhi, India. koulroshan@gmail.com

Received: 05 November 2022 Accepted: 11 January 2023 EPub Ahead of Print: 23 February 2023 Published: 03 May 2023 DOI: 10.25259/JNRP_47_2022

This is an open-access article distributed under the terms of the Creative Commons Attribution-Non Commercial-Share Alike 4.0 License, which allows others to remix, transform, and build upon the work non-commercially, as long as the author is credited and the new creations are licensed under the identical terms. ©2023 Published by Scientific Scholar on behalf of Journal of Neurosciences in Rural Practice

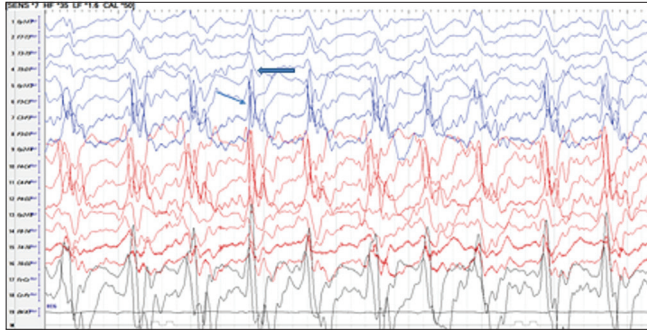


Figure 1: 32-year-old male with chronic liver disease due to ethanol and history of focal seizures in past. EEG revealed focal epileptic discharges over left temporal region (thin arrow) at the same time triphasic waves (thick arrow).

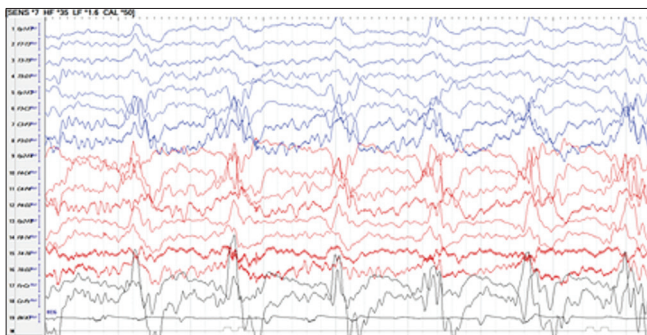


Figure 2: Previous patient, his EEG after improvement in encephalopathy showed no triphasic waves, but focal seizures persisted.

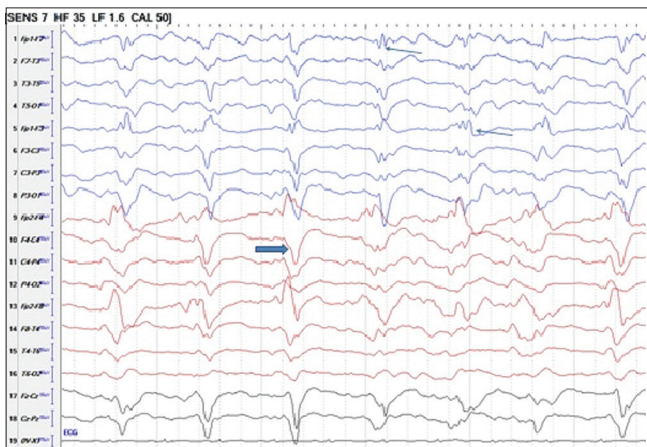

Figure 3: 50-year-old man with ethanol related chronic liver disease with HE. His EEG revealed generalized periodic discharges of triphasic waves (thick arrow) superimposed with seizure discharges (thin arrows). HE: Hepatic encephalopathy.

3. There is fronto-occipital time lag and whole T-wave complex lasts 0.32 s on average.^[6] These morphologic distinctions may help differentiate TWs from GSWCs. [Table 1] explains the differences between SWCs and T-waves.

Table 1: Differences between spike wave complexes and triphasic waves.

Features	Triphasic waves	Generalized spike wave complexes
Duration average	0.32 s (wider duration complex)	0.12 s (short duration complex)
Frequency of phases	NPN slower phases 2 and 3 dominant and high voltage	Higher first, second, and third
Phases	3	Steeper phase 2 slope
Site	More posterior frontocentral	Usually F3 F4
Time lag	Anteroposterior (fronto-occipital) time lag	No time lag
Phase reversal	Absent	Present
Painful stimulation	May enhance	No
Benzodiazepines	May suppress but no change in sensorium	Suppress and may improve sensorium

Declaration of patient consent

The authors certify that they have obtained all appropriate patient consent.

Financial support and sponsorship

Nil.

Conflicts of interest

There are no conflicts of interest.

REFERENCES

1. Kaplan PW, Sutter R. Affair with Triphasic waves-their striking presence, mysterious significance, and cryptic origins: What are they? *J Clin Neurophysiol* 2015;32:401-5.
2. Fernandez-Torre JL, Kaplan PW. Triphasic waves: Historical overview of an unresolved mystery. *J Clin Neurophysiol* 2021;38:399-409.
3. Bickford RG, Butt HR. Hepatic coma: The electroencephalographic pattern. *J Clin Invest* 1955;34:790-9.
4. Freund B, Kochetkov IS, Kaplan PW. White matter disease-The true source of Triphasic waves? *J Clin Neurophysiol* 2021;38:359-61.
5. Zhang K, Xu S, Zhou Y, Su T. Case report: Triphasic waves in a 9-year old girl with anti-NMDAR encephalitis. *Front Neurol* 2022;13:819209.
6. Kaplan PW, Schlattman DK. Comparison of triphasic waves and epileptic discharges in one patient with genetic epilepsy. *J Clin Neurophysiol* 2012;29:458-61.

How to cite this article: Koul R, Kumar S, Maiwall R. Spike wave complexes riding T-waves in generalized and focal pattern in two patients with hepatic encephalopathy. *J Neurosci Rural Pract* 2023;14:384-5.