

# Unilateral variant motor innervations of flexure muscles of arm

Yogesh AS, M Joshi, VK Chimurkar, RR Marathe

Department of Anatomy, Jawaharlal Nehru Medical College, Sawangi (Meghe), Wardha, Maharashtra, India

### ABSTRACT

The musculocutaneous nerve usually branches out from the lateral cord of brachial plexus. It innervates the coracobrachialis, biceps brachii and brachialis muscles and continues as the lateral cutaneous nerve of forearm without exhibiting any communication with the median nerve or any other nerve. We report unilateral variation in motor innervations of the left arm in a 58-year-old male cadaver. The musculocutaneous nerve was found to be absent. A muscular branch of the median nerve was supplying the coracobrachialis muscle. In the middle of arm, the median nerve was found to be branching out, bifurcating and supplying the long and short head of biceps. The median nerve was found to be giving a separate branch, which supplied the brachialis muscle and continued as the lateral cutaneous nerve of forearm. The right sided structures were found to be normal. Surgeons should keep such variations in mind while performing arm surgeries.

**Key words:** Anatomical variant, lateral cutaneous, musculocutaneous nerve, median nerve, nerve of forearm

DOI: 10.4103/0976-3147.63107

### Introduction

As per the medical and surgical aspects, the nerve supply of arm is very important. The musculocutaneous nerve (MCN) branches out from the lateral cord of brachial plexus. It passes through the Coracobrachialis muscle to innervate it and the biceps brachii muscle. Then it passes between the biceps brachii and brachialis muscle, gives a branch to supply later and continues as the lateral cutaneous nerve of forearm without exhibiting any communication with the median nerve (MN) or any other nerve. The MN passes through the anterior compartment of arm without innervating any flexure muscle of arm.<sup>[1]</sup>

Variations in the formation and branching pattern of the brachial plexus and the nerves supplying upper limb are common and have been reported continuously since the 19<sup>th</sup> century.<sup>[2]</sup> The anatomical variations of peripheral nerves are important to orthopedic surgeons, neurophysicians, physiotherapist and radiologists. Such comprehension is useful in nerve grafting, neurophysiological evaluation for diagnosing peripheral neuropathies.<sup>[3]</sup> The present variation was observed during routine dissection at the Anatomy department of Medical College of rural hospital.

### Case Report

In a 58-year-old male cadaver, the unilateral variation


in motor innervations of the left arm is reported. The pectoralis major and pectoralis minor muscles were removed to expose the brachial plexus. Skin, superficial and deep fascia, was excised to get a view of the arm contents. The musculocutaneous nerve was found to be absent. A branch of the MN was found to be supplying the coracobrachialis muscle. This branch of MN, arising from its lateral side, entered the substance of the coracobrachialis muscle [Figure 1]. In the middle of the arm, the MN was found to be giving the second branch from its lateral side. This branch of MN bifurcated and supplied the long and short head of biceps brachii muscle separately [Figure 2]. The MN was found to be giving a third branch in the arm, running downward and laterally in between the biceps brachii and brachialis muscle. This third branch was supplied the brachialis muscle and continued as the lateral cutaneous nerve of forearm. Dissection was continued to expose the entire brachial plexus from the origin and it was found to be normal. The right sided structures were found to be normal.

### Discussion

In this case report, the motor branches of flexure muscles of the left arm were found to be arising from the MN. The MN branch supplying the brachialis muscle was found to be continuing as the lateral cutaneous nerve. Thus, the MCN was replaced by the MN branches. The origin

#### Address for correspondence:

Dr. Yogesh AS, Department of Anatomy, JN Medical College, Sawangi Meghe, Wardha, Maharashtra, India.  
E-mail: dryogeshas@rediffmail.com



**Figure 1:** Dissection of the axilla and anterior compartment of arm showing the variation of Median nerve. (BA: Brachial artery; Br: Brachialis muscle; CBr: Coracobrachialis muscle; DL: Deltoid; LhBB: Long head of Biceps brachii muscle; MN: Median nerve; ShBB: Short head of Biceps brachii muscle; 1: Branch to coracobrachialis; 2: Branch to Biceps brachii; 3: Third branch of median nerve; 4: Branch to brachialis; 5: Lateral cutaneous nerve of forearm).

of brachial plexus was found to be normal. Variants of the branching pattern of MCN and MN have been well described by many authors.<sup>[4,5]</sup> Le Minor (1992) classified these variations into five types:<sup>[6]</sup>

Type 1: No communication between MN and MCN.

Type 2: The fibers of the medial root of the MN pass through the MCN and join the MN in the middle of the arm.

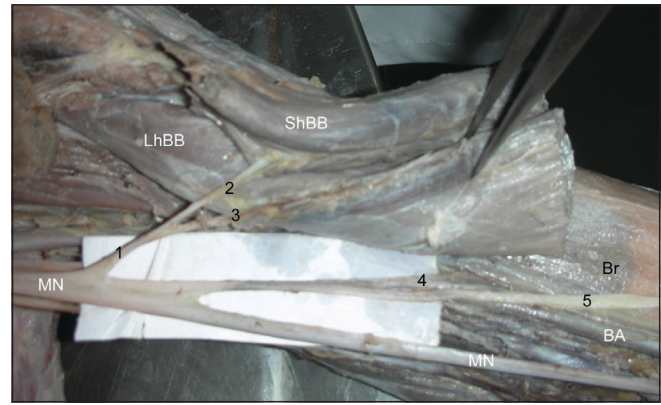
Type 3: The fibers of the lateral root of the MN pass through the MCN and after some distance leave it to form the lateral root of the MN.

Type 4: The MCN fibers join the lateral root of the MN and after some distance the MCN arise from the MN.

Type 5: The MCN is absent and all the MCN fibers pass through lateral root of MN; fibers to the muscles supplied by MCN branch out directly from MN. In this type, the MCN does not pierce the coracobrachialis muscle.

Present findings indicate the presence of Le Minor Type V variant. Surgeons should keep such possible variations of the MCN and the MN surgeon in mind during constructive shoulder arthroplasty and treating shoulder dislocations.

The existence of this variation described in our case report may be attributed to the random factors influencing the mechanism of formation of the limb muscles and the peripheral nerves during the embryonic life. In the context that ontogeny recapitulates phylogeny; it is possible that



**Figure 2:** Closure view showing nerve supply of biceps brachii and brachialis muscles. (BA: Brachial artery; Br: Brachialis muscle; LhBB: Long head of Biceps brachii muscle; MN: Median nerve; ShBB: Short head of Biceps brachii muscle; 1: Branch to Biceps brachii; 2: Branch to Short head of Biceps brachii; 3: Branch to Long head of Biceps brachii; 4: Branch to brachialis; 5: Lateral cutaneous nerve of forearm)

the variation seen in the current study is the result of developmental anomaly. In the human being, the forelimb muscles develop from the mesenchyme of paraxial mesoderm in the fifth week of the intrauterine life.<sup>[7]</sup> The regional expression of five Hox D (Hox D 1 to Hox D 5) genes is responsible for upper limb development.<sup>[8]</sup> The motor axons arrive at the base of the limb bud; they mix to form the brachial plexus in the upper limb. The growth cones of the axons continue in the limb bud.<sup>[7]</sup> The guidance of the developing axons is regulated by the expression of chemo-attractants and chemo-repulsant in highly coordinated sight specific fission. Tropic substances attract the correct growth cones or support the viability of the growth cones that happen to take the right path. Tropic substances include the brain-derived neurotropic growth factor, *c-kit ligand*, *neutrin-1*, *neutrin-2* etc.<sup>[9]</sup> The significant variations in nerve pattern may be the result of altered signaling between the mesenchymal cells and the neuronal growth cones or circulatory factors at the time of fission of brachial plexus cords.

### Clinical significance

Meticulous knowledge of possible variations of the MCN and the MN may endow us with valuable help in the management of traumatology of the shoulder joint, specifically constructive shoulder arthroplasty and shoulder dislocations and arm, as well as in circumventing iatrogenic damage during repair operations of these regions.

### References

1. Standring S, Borley NR, Collins P, Crossman AR, Gatzoulis MA, Healy JC, *et al.* Gray's Anatomy. Pectoral region, shoulder region and axilla. 40<sup>th</sup> ed. London: Churchill Livingstone; 2008. p. 791-822.
2. Linell EA. The distribution of nerves in the upper limb, with reference to

- variabilities and their clinical significance. *J Anat* 1921;55:79-112.
3. Wiberg M, Hazari A, Ljungberg C, Pettersson K, Backman C, Nordh E, *et al.* Sensory recovery after hand reimplantation: A clinical, morphological, and neurophysiological study in humans. *Scand J Plast Reconstr Surg Hand Surg* 2003;37:163-73.
  4. Chauhan R, Roy TS. Communication between the Median and musculocutaneous nerve: A case report. *J ASI* 2002;51:1-6.
  5. Choi D, Rodriguez NM, Vazquez T, Parkin I, Sanudo JR. Patterns of connection between the musculocutaneous and Median nerves in the axilla and in arm. *Clin Anatomy* 2002;15:11-7.
  6. Le MJ. A rare variant of Median and musculocutaneous nerves in man. *Ach Anat Histol Embryol* 1992;73:33-42.
  7. Moore KL, Persaud TV. Before we are born. 7<sup>th</sup> ed. The musculoskeletal system. Philadelphia: Saunders Elsevier; 2003. p. 243-4.
  8. Morgan BA, Tabin C. Hox genes and growth: early and late roles in limb bud morphogenesis. *Dev Suppl* 1994:181-6.
  9. Larson WJ. Human embryology. 3<sup>rd</sup> ed. Development of peripheral nervous system. Pennsylvania: Churchill Livingstone; 2001. p. 115-6.

**Source of Support:** Nil, **Conflict of Interest:** None declared.