

# Morphometric analysis of posterior fossa and foramen magnum

Gautam Kanodia, Vijay Parihar, Yad R Yadav, Pushp R Bhatele<sup>1</sup>, Dhananjay Sharma<sup>2</sup>

Departments of Neurosurgery, <sup>2</sup>Surgery, <sup>1</sup>Radiodiagnosis, NSCB Medical College and MP MRI Jabalpur, Madhya Pradesh, India

## ABSTRACT

**Introduction:** Configuration and size of the foramen magnum and posterior fossa plays an important role in the pathophysiology of the posterior fossa and craniovertebral junction disorders. This study is aimed to find out various dimensions of the foramen magnum and posterior fossa. **Materials and Methods:** This is a prospective study of 100 consecutive normal computerized tomography (CT) scans of posterior fossa and 100 dry adult skulls without any bony abnormality. The posterior fossa volume was calculated by  $abc/2$  in method 1 and by advanced work station of CT scan in method 2. Various dimensions of posterior fossa and foramen magnum were also studied. **Results:** Age ranged from 16 to 89 years with a mean of 51.3 years. Mean height of posterior fossa were 3.01 cm ( $\pm 0.22$ ) and 3.52 ( $\pm 0.43$ ) cm in dry skull and CT scan group, respectively ( $P < 0.0001$ ). Mean volume of posterior fossa were 157.88 ( $\pm 27.94$ ) cm<sup>3</sup> and 159.58 ( $\pm 25.73$ ) cm<sup>3</sup> by method 1 and method 2, respectively ( $P > 0.05$ ). All the dimensions of posterior fossa and foramen magnum were larger in male as compared to female. Mean anteroposterior (AP), transverse diameter and surface area of the foramen magnum were 3.31 ( $\pm 0.35$ ) cm, 2.76 ( $\pm 0.31$ ) cm, and 729.15 ( $\pm 124.87$ ) mm<sup>2</sup>, respectively, in CT scan group as compared to 3.41 ( $\pm 0.29$ ) cm, 2.75 ( $\pm 0.25$ ) cm, and 747.67 ( $\pm 108.60$ ) mm<sup>2</sup>, respectively, in dry skull group. **Conclusion:** Normal values of posterior fossa and foramen magnum could serve as a future reference. Dry skull dimensions could be different from CT scan measurement. More studies are needed as there could be variations in dimensions in different regions in India

**Key words:** Foramen magnum, posterior cranial fossa, skull

## Introduction

Configuration and size of the foramen magnum and posterior fossa (PF) plays an important role in the pathophysiology of various disorders of the PF and craniovertebral junction. Stenosis of foramen magnum causes brainstem compression manifested by respiratory complications, lower cranial nerve dysfunctions, upper and lower extremity paresis, hypo- or hypertonia, hyperreflexia, or clonus.<sup>[1-3]</sup> Thus, a fundamental knowledge of normal anatomy of this region is important to the clinician for diagnosis and treatment. The aim of our study was to find out various measurements of the foramen magnum and PF in Indian population. These

results could help in the better diagnosis, classification, and treatment of diseases related to this region and serve as a future reference defining an anatomic range. Although we agree that India is a vast country and the dimensions may vary in different regions. Although alignment of upper and lower cervical spine has been described,<sup>[4]</sup> there is no anatomical study about the dimensions of PF and foramen magnum for the Indian population to the best of our knowledge.

## Materials and Methods

The study was conducted in a tertiary referral hospital from July 2010 to October 2011 in both adult human and adult human dry skulls. Hundred consecutive head injury patients with normal computerized tomography (CT) scans (without any bony or soft-tissue abnormality) admitted to Neurosurgery Unit were included in the study. Those with fracture or hematoma of PF were excluded from the study. Hundred dry adult skulls without any gross bony abnormality were also studied.

Access this article online	
Quick Response Code:	Website: www.ruralneuropractice.com
	DOI: 10.4103/0976-3147.102602

### Address for correspondence:

Dr. Yad Ram Yadav, Department of Neurosurgery, NSCB (Government) Medical College, Jabalpur, Madhya Pradesh, India.  
E-mail: yadavyr@yahoo.co.in

The dry skulls were obtained from the Department of Anatomy from the bone bank. Dry skulls were not taken directly from dead bodies.

Inferior basal view was observed for the measurement of foramen magnum in the dry skulls. The anteroposterior (AP) and the transverse diameter were measured using a vernier caliper. The area of the foramen magnum was calculated using formula  $\pi r^2$ , where  $r$  is average radius calculated from AP and transverse diameter. The normal ranges of dimensions of the foramen magnum were also noted. The height of the PF was measured as the perpendicular distance between twinning's line and McRae line [Figure 1]. PF volume (PFV) was measured by  $abc/2$  where  $a$  is the height,  $b$  is anteroposterior diameter, and  $c$  is transverse diameter of the PF.<sup>[5]</sup>

In adult human PFV along with both the measurements (foramen magnum dimensions and PF height) were studied by performing a CT of the skull. The CT scans of human subjects were performed on a 16-row bright speed CT scan. The PFV was measured by two methods. In first method, volume was calculated by  $abc/2$ , where  $a$  is the height,  $b$  is AP diameter, and  $c$  is transverse diameter of the PF.<sup>[5]</sup> In second method, PFV was calculated by an advanced work station of 16-row bright speed CT scan. The data obtained by the CT scan of foramen magnum and PF were compared with the dry skull. Data were entered in Microsoft Excel 2007 worksheet and statistical analysis was performed by IBM SPSS statistics 19 version. Independent sample  $t$  test and ANOVA (analysis of variance) test were used.  $P < 0.05$  was considered as significant.

## Results

Volume and the height of the PF and the dimensions of the foramen magnum were recorded in 100 head injury patients without any pathology of PF and 100 dry skulls. Age ranged from 16 to 89 years with a mean of 51.3 years. There were 64 male patients of head injury. There was no difference in dimensions of the PF and foramen magnum in various age groups, as shown in Tables 1 and 2. All the dimensions of PF and foramen magnum were larger in male as compared to female [Table 3]. These differences were statistically significant in all except PF height, as shown in Table 3. The mean height of PF was 3.52 cm ( $\pm 0.43$ ) in head injury patients [Table 4]. The mean surface area, AP, and transverse diameter of foramen magnum were

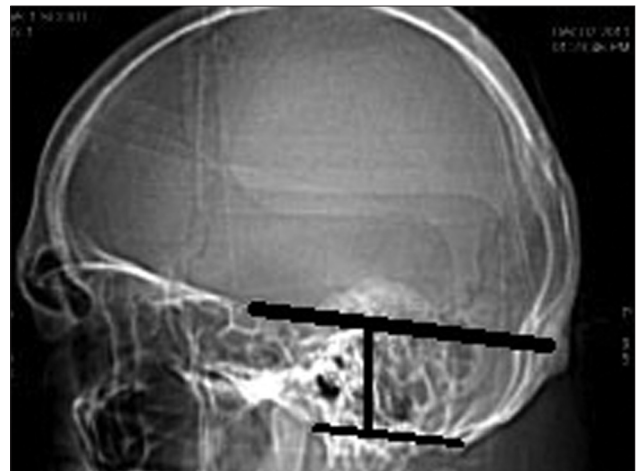


Figure 1: Height of posterior fossa

Table 1: Posterior fossa dimensions according to various age groups in head injury

Age groups	Posterior fossa height (mean $\pm$ SD)	P value	Posterior fossa volume method 1 (mean $\pm$ SD)	P value	Posterior fossa volume method 2 (mean $\pm$ SD)	P value
16 $\leq$ 25 (N = 9)	3.50 ( $\pm 0.18$ )	0.24	157.01 ( $\pm 17.20$ )	0.48	159.23 ( $\pm 37.70$ )	0.28
25–34 (N = 10)	3.39 ( $\pm 0.35$ )		153.63 ( $\pm 22.75$ )		151.36 ( $\pm 23.98$ )	
35–44 (N = 15)	3.47 ( $\pm 0.49$ )		157.08 ( $\pm 32.02$ )		150.87 ( $\pm 16.51$ )	
45–54 (N = 19)	3.33 ( $\pm 0.45$ )		147.52 ( $\pm 29.02$ )		157.19 ( $\pm 21.66$ )	
55–64 (N = 21)	3.60 ( $\pm 0.48$ )		159.37 ( $\pm 31.81$ )		158.79 ( $\pm 25.93$ )	
65–75 (N = 19)	3.67 ( $\pm 0.45$ )		167.59 ( $\pm 27.99$ )		171.16 ( $\pm 28.24$ )	
76–89 (N = 7)	3.61 ( $\pm 0.31$ )		164.03 ( $\pm 18.63$ )		167.85 ( $\pm 25.68$ )	

Table 2: Foramen magnum dimensions according to age groups in head injury

Age group	AP Diameter in cm (mean $\pm$ SD)	P value	Transverse Diameter in cm (mean $\pm$ SD)	P value	Surface area in mm <sup>2</sup> (mean $\pm$ SD)	P value
16 $\leq$ 25 (N = 9)	3.17 $\pm$ 0.39	0.88	2.50 $\pm$ 0.33	0.22	636.33 $\pm$ 131.35	0.43
25–34 (N = 10)	3.32 $\pm$ 0.44		2.82 $\pm$ 0.37		745.83 $\pm$ 133.10	
35–44 (N = 15)	3.32 $\pm$ 0.34		2.77 $\pm$ 0.33		734.89 $\pm$ 134.43	
45–54 (N = 19)	3.31 $\pm$ 0.42		2.76 $\pm$ 0.30		728.49 $\pm$ 128.03	
55–64 (N = 21)	3.30 $\pm$ 0.33		2.84 $\pm$ 0.29		743.76 $\pm$ 116.75	
65–75 (N = 19)	3.33 $\pm$ 0.25		2.76 $\pm$ 0.27		732.19 $\pm$ 116.60	
76–89 (N = 7)	3.43 $\pm$ 0.29		2.79 $\pm$ 0.25		762.09 $\pm$ 120.93	

729.15 mm<sup>2</sup> (±124.87), 3.31 cm (±0.35) and 2.76 cm (±0.31), respectively, [Table 4] in head injury patients. The mean value of PFV were 157.88 (±27.94) cm<sup>3</sup> (range 98.75–216.88 cm<sup>3</sup>) and 159.58 (±25.73) cm<sup>3</sup> (range 116.03–252.99 cm<sup>3</sup>) measured by method 1 and method 2, respectively. However, the difference was not significant statistically ( $P > 0.05$ ).

The mean height and volume of PF were 3.01 cm (±0.22) (range 2.5–4.0 cm) and 122.49 (±14.66), respectively, in dry skull [Table 4]. Both these dimensions in dry skull were significantly smaller than in the CT scan group ( $P < 0.0001$ ). The mean surface area, AP, and transverse diameter of foramen magnum were 747.67 mm<sup>2</sup> (±108.60), 3.41 cm (±0.29), and 2.75 cm (±0.25), respectively, in dry skull [Table 4]. AP diameter of dry skull was larger than CT scan group ( $P = 0.036$ ), while there was no significant difference in transverse diameter and surface area of the two groups [Table 4]. A Whisker–Boxplot for various

dimensions of PF and foramen magnum by gender and comparison of CT scan and dry skull were also done [Graphs 1–5].

## Discussion

Pathologies of the PF and craniovertebral junctions are very common. Knowledge of anatomy of this region and the normal range is important in the proper planning of the management. We all know that there are normal variations amongst various races, religions, body habitus, and gender, geographical, and genetic factors. Although there are studies on normal dimensions of the PF and foramen magnum, there is no study in the Indian population.

### PF dimensions

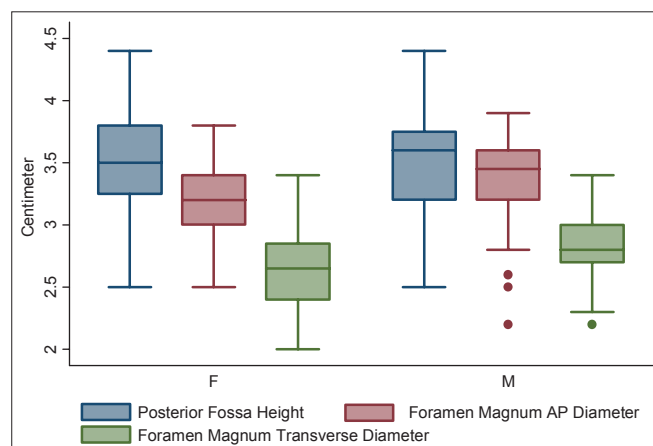
The mean height of PF in dry skull was smaller as compared to CT scan ( $P = < 0.0001$ ). Lower range of dimensions in dry skull could be due to the shrinkage.<sup>[6]</sup>

**Table 3: Posterior fossa and foramen magnum dimensions in head injury patients in relation to gender**

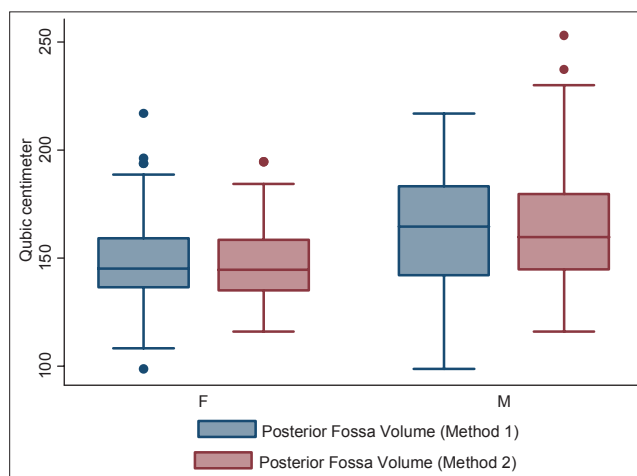
Dimensions	Male (mean ± SD) N = 64	Female (mean ± SD) N = 36	P value
Posterior fossa volume in cm <sup>3</sup>			
A, Method 1	162.88 (±27.68)	148.99 (±26.51)	$P = 0.016$
B, Method 2	165.68 (±27.16)	148.73 (±18.86)	$P < 0.0001$
Posterior fossa height in cm	3.55 (±0.43)	3.46 (±0.44)	$P = 0.327$
Foramen Magnum dimensions			
A, AP diameter in cm	3.38 (±0.34)	3.19 (±0.33)	$P = 0.009$
B, Transverse diameter in cm	2.82 (±0.26)	2.66 (±0.35)	$P = 0.019$
C, Surface area in mm <sup>2</sup>	758.60 (±115.05)	676.81 (±125.99)	$P = 0.001$

**Table 4: Posterior fossa and foramen dimensions in CT scan of head injury patients and dry skull**

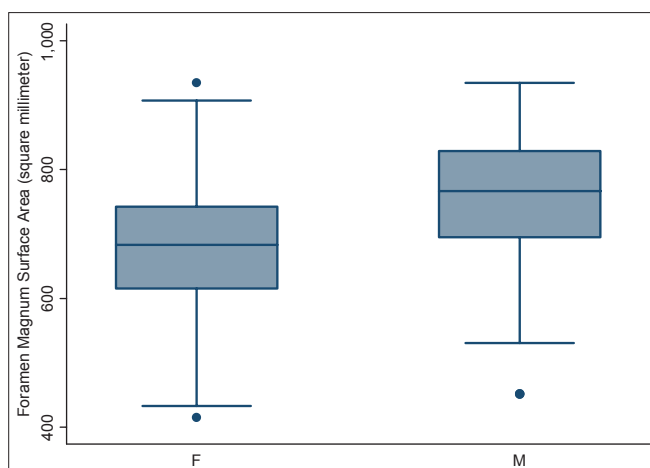
Dimensions	CT scan (mean ± SD) N = 100	Dry skull (mean ± SD) N = 100	P value
Posterior fossa volume in cm <sup>3</sup>	157.88 (±27.94)	122.49 (±14.66)	$< 0.0001$
Posterior fossa height in cm	3.52 (±0.43)	3.01 (±0.22)	$< 0.0001$
Foramen magnum dimensions			
A, AP diameter in cm	3.31 (±0.35)	3.41 (±0.29)	0.036
B, Transverse diameter in cm	2.76 (±0.31)	2.75 (±0.25)	0.762
C, Surface area in mm <sup>2</sup>	729.15 (±124.87)	747.67 (±108.60)	0.264



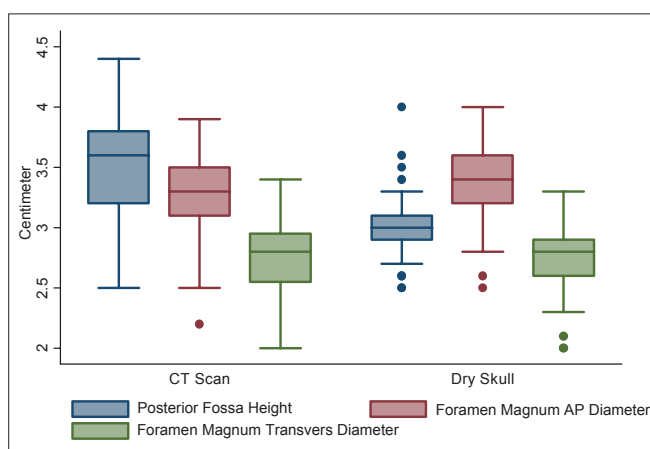
**Graph 1: Dimensions of posterior fossa and foramen magnum in head injury patients in different genders**



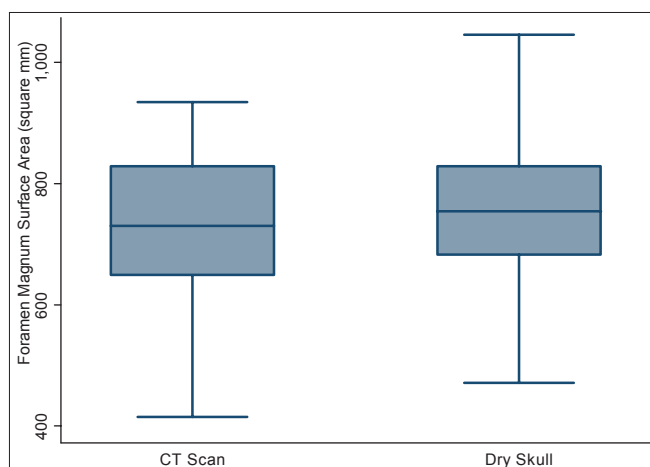
**Graph 2: Posterior fossa volume by methods 1 and 2 in male and female head injury patients**



**Graph 3:** Surface area of foramen magnum in male and female head injury patients



**Graph 4:** Posterior fossa height, AP, and transverse diameters of foramen magnum in head injury patients and dry skull



**Graph 5:** Surface area of foramen magnum in head injury patients and dry skull

Height of PF can be measured by MRI also, using soft-tissue landmarks from splenium of corpus callosum to the McRae Line.<sup>[7]</sup> The height of PF measured by MRI was more<sup>[7]</sup> and seems to be more useful clinically.

The mean volume of PF by method 1 was smaller as compared to method 2, although the difference was statistically not significant ( $t = 0.448$  and  $P = 0.655$ ). Calculation by method 1 is simple and it is already in use to calculate the volume of intracranial hematoma and abscess,<sup>[5,8]</sup> while the calculation by CT scan using in built software could give more accurate value.

**Clinical implications of posterior cranial fossa height and volume**

The overcrowding of posterior cranial fossa (PCF) can be determined if the normal range of the volume and height is available. Patients with hypoplasia of the bony structures could present at early age. The severity of presentation could be more with more overcrowding in congenital anomalies like Chiari Malformation 1 (CM 1). Short height of PF and underdeveloped bony structures could lead to downward herniation of the contents in adult<sup>[9-14]</sup> and in pediatric patients.<sup>[15,16]</sup> This could result in syringomyelia due to obstruction of the normal CSF circulation.<sup>[17-20]</sup> Grant *et al.* reported that the myelomeningocele was associated with tonsillar herniation and a smaller PF as compared to control fetuses. Antenatal surgical repair corrected both abnormalities.<sup>[21]</sup> Noudel *et al.* observed that the occipital hypoplasia was the main cause of overcrowding within the PCF. Basioccipital shortness was a cardinal feature of the shallow PCF. This could proceed from a congenital disorder of the cephalic mesoderm of the parachordal plate or occur later in the infancy because of premature stenosis of the sphenoccipital synchondrosis.<sup>[22]</sup> Badie *et al.*<sup>[23]</sup> reported that the ratio of PFV to supratentorial volume (PF ratio) [PFR] was smaller in most patients with CM 1. They concluded that a smaller PF may be a primary cause of tonsillar herniation. Patients with CM I who have smaller PFRs tend to develop symptoms earlier than those with normal values. They also observed that the patients with smaller PFRs tend to respond better to suboccipital decompression. Sgouros *et al.*<sup>[24]</sup> reported that the children with isolated CM 1 did not have a smaller PFV than normal, whereas children with both CM 1 and syringomyelia had a significantly smaller PFV than normal. They suggested that the two subgroups may represent different phenotypic expression or even a different pathogenesis. Trigylidas *et al.*<sup>[25]</sup> observed that the mean PFV/ intra cranial volume (ICV) ratio for all the CM 1 patients was statistically smaller than that of the control patients. On the other hand Tubbs *et al.*<sup>[26]</sup> performed volumetric analysis in a family of CM 1, documented in 4 generations. They observed that it is not necessary that patients with a CM 1 will have a smaller PCF volume. Goel *et al.*<sup>[27]</sup> reported that small PFV were associated with Chiari malformation in basilar invasion while patients with only basilar invasion without Chiari

malformation had normal PFV. They recommended decompression of the foramen magnum in small PFV group patients.

### Foramen magnum dimensions

The mean AP diameter of foramen magnum was slightly larger in dry skull as compared to CT Scans. Mean transverse diameter was same in dry skull and CT Scans. The mean surface area of foramen magnum was more in dry skull as compared to CT scan. Higher value of surface area in dry skull could be due to higher range of AP diameter in dry skull. This difference was not statistically significant ( $t = 1.119$ ,  $P = 0.264$ ). Higher range of AP diameter in dry skulls could be due to demineralization of dry skulls. AP, transverse diameter, and surface area in Tubbs *et al.* series were 3.1 (2.5–3.7 cm), 2.7 cm (2.4–3.5 cm), and 558 mm<sup>2</sup> (385–779 mm<sup>2</sup>), respectively.<sup>[6]</sup> The variation in our results and in Tubbs *et al.* series could be due to the difference in races, habitus, geographical, and genetic factors. Lang<sup>[28]</sup> classified the shapes of foramen magnum into five groups: (a) two semicircles, (b) an elongated circle, (c) egg-shaped, (d) rhomboidal, and (e) rounded. He found that the average AP and transverse diameter of the foramen were 3.5 and 3 cm, respectively. Our findings were consistent with the Lang *et al.* series.

### Clinical implications of dimensions of foramen magnum

The foramen magnum is a fundamental component in the complex interaction of bony, ligamentous, and muscular structures composing the craniovertebral junction. Shape and size of the foramen is critical parameters for the manifestation of clinical signs and symptoms in craniocervical pathology. The AP and transverse diameters of the foramen magnum have been found to be independent risk factors in patients with craniocervical anomalies.<sup>[1,29-31]</sup>

The configuration of the foramen magnum in patients with Chiari I and Chiari II malformations has been found to be larger than in the normal population.<sup>[19]</sup> Another analysis based on semiaxial cranial x-rays demonstrated a significantly larger transverse diameter of the foramen magnum in 35 children with verified Chiari I malformation, as compared to the control group.<sup>[32]</sup> However, Furtado *et al.* found no statistical difference in the area and linear dimensions of the foramen magnum in children with Chiari I malformations and control groups.<sup>[33]</sup> Early developments of symptoms were observed in shorter AP diameters of foramen magnum.<sup>[34]</sup> Patients with stenosis of foramen magnum, such as craniometaphyseal dysplasia, Jeune's asphyxiating thoracic dystrophy, and spherophakia-brachymorphism (Marchesani's syndrome),<sup>[35-37]</sup> Beare-Stevenson syndrome (a craniofacial syndrome characterized by hypertrophy

of the bony margins),<sup>[38]</sup> could develop early and severe symptoms. Tubbs *et al.* hypothesized that the anatomy of the craniocervical region may be different in CM 1 patients with syringomyelia who develop syringobulbia compared to other patients of CM 1 with and without syringomyelia. Although no single morphometrical difference was found in patients with CM 1 and syringobulbia compared to other patients with CM 1 in their series.<sup>[39]</sup>

Understanding the bony anatomy of foramen magnum is important for the transcondylar approach. Muthukumar *et al.* found that the occipital condyle can be safely drilled for a distance of 12 mm from the posterior margin before encountering the hypoglossal canal. In 20% of the skulls, the occipital condyle protrudes significantly into the foramen magnum. Wide and sagittally inclined occipital condyles, medially protuberant occipital condyles along with a foramen magnum index of more than 1.2, will require much more extensive bony resection than otherwise.<sup>[40]</sup>

### Strengths and limitations of study

The strength of our study is large sample size. We did the morphometric analysis in dry skull as well as in CT scan of head injury patients without any bony or soft tissue abnormality. This study does have some limitations. Pediatric age group, which is the predominant age group for anomalies of this region, has not been studied. The head injury group and the dry skull group may not be comparable as we could not determine age and gender in the dry skull

### Conclusion

Normal ranges of various dimensions of PF and foramen magnum for Indian population were determined which could serve as future reference. Dry skull dimensions could be different from CT scan measurement due to shrinkage or demineralization.

### References

1. Bagley CA, Pindrik JA, Bookland MJ, Camara-Quintana JQ, Carson BS. Cervicomedullary decompression for foramen magnum stenosis in achondroplasia. *J Neurosurg* 2006;104(3 Suppl):166-72.
2. Dickman C, Spetzler RF, Sonntag VK. *Surgery of the craniovertebral junction*. 1<sup>st</sup> ed. New York, NY: Thieme Medical Publishers; 1998.
3. Wang H, Rosenbaum AE, Reid CS, Zinreich SJ, Pyeritz RE. Pediatric patients with achondroplasia: CT evaluation of the craniocervical junction. *Radiology* 1987;164:515-9.
4. Sherekar SK, Yadav YR, Basoor AS, Baghel A, Adam N. Clinical implications of alignment of upper and lower cervical spine. *Neuro India* 2006;54:264-7.
5. Kothari RU, Brott T, Broderick JP, Barsan WG, Sauerbeck LR, Zuccarello M, *et al.* The ABCs of measuring intracerebral hemorrhage volumes. *Stroke* 1996;27:1304-5.

6. Tubbs RS, Griessenauer CJ, Loukas M, Shoja MM, Cohen-Gadol AA. Morphometric analysis of the foramen magnum: An anatomic study. *Neurosurgery* 2010;66:385-8.
7. Aydin S, Hanimoglu H, Tanriverdi T, Yentur E, Kaynar MY. Chiari type I malformations in adults: A morphometric analysis of the posterior cranial fossa. *Surg Neurol* 2005;64:237-41.
8. Yadav YR, Basoor A, Jain G, Nelson A. Expanding traumatic intracerebral contusion/hematoma. *Neurol India* 2006;54:377-81.
9. Meadows J, Kraut M, Guarnieri M, Haroun RI, Carson BS. Asymptomatic Chiari type I malformations identified on magnetic resonance imaging. *J Neurosurg* 2000;92:920-6.
10. Milhorat TH, Chou MW, Trinidad EM, Kula RW, Mandell M, Wolpert C, et al. Chiari I malformation redefined: Clinical and radiographic findings for 364 symptomatic patients. *Neurosurgery* 1999;44:1005-17.
11. Nishikawa M, Sakamoto H, Hakuba A, Nakanishi N, Inoue Y. Pathogenesis of Chiari malformation: A morphometric study of the posterior cranial fossa. *J Neurosurg* 1997;86:40-7.
12. Schady W, Medcalfe RA, Butler F. The incidence of craniocervical bony anomalies in the adult Chiari I malformation. *J Neurosurg* 1987;82:193-203.
13. Stovner LJ, Bergan U, Nilsen G, Sjaastad O. Posterior cranial fossa dimensions in the Chiari I malformation: Relation to pathogenesis and clinical presentation. *Neuroradiology* 1993;35:113-8.
14. Vega A, Quintana F, Berciano J. Basichondrocranium anomalies in adult Chiari type I malformation: A morphometric study. *J Neurol Sci* 1990;99:137-45.
15. Tubbs RS, Elton S, Grabb P, Dockery SE, Bartolucci AA, Oakes WJ. Analysis of the posterior fossa in children with the Chiari I malformation. *Neurosurgery* 2001;48:1050-5.
16. Wu YW, Chin CT, Chan KM, Barkovich AJ, Ferriero DM. Pediatric Chiari I malformations: Do clinical and radiological features correlate? *Neurology* 1999;53:1271-6.
17. Ball MJ, Dayan AD. Pathogenesis of syringomyelia. *Lancet* 1972;2:799-801.
18. du Boulay G, Shah SH, Currie JC, Logue V. The mechanism of hydromyelia in Chiari type I malformations. *Br J Radiol* 1974;47:579-87.
19. Gardner WJ, Goodall RJ. The surgical management of Arnold-Chiari malformation in adults. An explanation of its mechanism and importance of encephalography in diagnosis. *J Neurosurg* 1950;7:199-206.
20. Oldfield EH, Muraszko K, Shawker TH, Patronas NJ. Pathophysiology of syringomyelia associated with Chiari I malformation of the cerebellar tonsils. Implications for diagnosis and treatment. *J Neurosurg* 1994;80:3-15.
21. Grant RA, Heuer GG, Carrión GM, Adzick NS, Schwartz ES, Stein SC, et al. Morphometric analysis of posterior fossa after in utero myelomeningocele repair. *J Neurosurg Pediatr* 2011;7:362-8.
22. Noudel R, Jovenin N, Eap C, Scherpereel B, Pierot L, Rousseaux P. Incidence of basioccipital hypoplasia in Chiari malformation type I: Comparative morphometric study of the posterior cranial fossa. *Clinical article. J Neurosurg* 2009;111:1046-52.
23. Badie B, Mendoza D, Batzdorf U. Posterior fossa volume and response to suboccipital decompression in patients with Chiari I malformation. *Neurosurgery* 1995;37:214-8.
24. Sgouros S, Kountouri M, Natarajan K. Posterior fossa volume in children with Chiari malformation Type I. *J Neurosurg* 2006;105(2 Suppl):101-6. Comment in *J Neurosurg* 2007;106(4 Suppl):329;author reply 329-30.
25. Trigylidas T, Baronia B, Vassilyadi M, Ventureyra EC. Posterior fossa dimension and volume estimates in pediatric patients with Chiari I malformations. *Childs Nerv Syst* 2008;24:329-36.
26. Tubbs RS, Hill M, Loukas M, Shoja MM, Oakes WJ. Volumetric analysis of the posterior cranial fossa in a family with four generations of the Chiari malformation Type I. *J Neurosurg Pediatr* 2008;1:21-4.
27. Goel A, Bhatjwale M, Desai K. Basilar invagination: A study based on 190 surgically treated patients. *J Neurosurg* 1998;88:962-8.
28. Lang J. *Clinical anatomy of the posterior cranial fossa and its foramina*. Stuttgart, Germany: Thieme; 1991.
29. Hecht JT, Nelson FW, Butler IJ, Horton WA, Scott CI Jr, Wassman ER, et al. Computerized tomography of the foramen magnum: Achondroplastic values compared to normal standards. *Am J Med Genet* 1985;20:355-60.
30. Hunter AG, Bankier A, Rogers JG, Silience D, Scott CI Jr. Medical complications of achondroplasia: A multicentre patient review. *J Med Genet* 1998;35:705-12.
31. Pauli RM, Horton VK, Glinki LP, Reiser CA. Prospective assessment of risks for cervicomedullary-junction compression in infants with achondroplasia. *Am J Hum Genet* 1995;56:732-44.
32. Bliesener JA, Schmidt LR. Normal and pathological growth of the foramen occipitale magnum shown in the plain radiography. *Pediatr Radiol* 1980;10:65-9.
33. Furtado SV, Thakre DJ, Venkatesh PK, Reddy K, Hegde AS. Morphometric analysis of foramen magnum dimensions and intracranial volume in pediatric Chiari I malformation. *Acta Neurochir (Wien)* 2010;152:221-7.
34. Menezes AH. Primary craniovertebral anomalies and the hindbrain herniation syndrome (Chiari I): Data base analysis. *Pediatr Neurosurg* 1995;23:260-9.
35. Boltshauser E, Schmitt B, Wichmann W, Valavanis A, Sailer H, Yonekawa Y. Cerebellomedullary compression in recessive craniometaphyseal dysplasia. *Neuroradiology* 1996;38 [Suppl 1]:S193-5.
36. Ferrier S, Nusslé D, Friedli B, Ferrier PE. Marchesani's syndrome (spherophakia-brachymorphism). *Helv Paediatr Acta* 1980;35:185-98.
37. Knisely AS, Steigman CK. Stenosis of the foramen magnum and rostral spinal canal, with spinal cord deformity, in Jeune's asphyxiating thoracic dystrophy. *Pediatr Pathol* 1989;9:299-305.
38. Upmeyer S, Bothwell M, Tobias JD. Perioperative care of a patient with Beare-Stevenson syndrome. *Paediatr Anaesth* 2005;15:1131-6.
39. Tubbs RS, Bailey M, Barrow WC, Loukas M, Shoja MM, Oakes WJ. Morphometric analysis of the craniocervical juncture in children with Chiari I malformation and concomitant syringobulbia. *Childs Nerv Syst* 2009;25:689-92.
40. Muthukumar N, Swaminathan R, Venkatesh G, Bhanumathy SP. A morphometric analysis of the foramen magnum region as it relates to the transcondylar approach. *Acta Neurochir (Wien)* 2005;147:889-95.

**How to cite this article:** Kanodia G, Parihar V, Yadav YR, Bhatele PR, Sharma D. Morphometric analysis of posterior fossa and foramen magnum. *J Neurosci Rural Pract* 2012;3:261-6.  
**Source of Support:** Nil. **Conflict of Interest:** None declared.