

Case Report

Crescent-shaped intracranial hemorrhage in cerebral venous sinus thrombosis: A case report and review of literature

Muhammad Yunus Amran¹ , Yusran Ady Fitrah¹

¹Department of Neurology, Faculty of Medicine, Hasanuddin University, Makassar, Indonesia.

ABSTRACT

Cerebral venous sinus thrombosis (CVST) is a rare but serious condition involving blood clots in the cerebral venous system often linked to prothrombotic states. It can result in complications such as intracranial hemorrhage and neurological deficits. We present the case of a 16-year-old female with CVST affecting the superior sagittal sinus, who experienced severe headaches and seizures. Initial computed tomography imaging showed a hematoma in the right frontal lobe, suggesting sinus and cortical vein thrombosis. Magnetic resonance imaging, magnetic resonance angiography, and magnetic resonance venography confirmed subacute hemorrhage with perifocal edema, and cerebral angiography validated the diagnosis. Elevated D-dimer levels supported the findings. The patient was treated with fondaparinux and later transitioned to oral warfarin, leading to clinical improvement and reduced D-dimer levels within a week. This case highlights the importance of early diagnosis and anticoagulation therapy, even in hemorrhagic cases, to prevent long-term complications and emphasizes the need for awareness of CVST in similar scenarios.

Keywords: Cerebral venous sinus thrombosis, Crescent-shaped intracranial hemorrhage, Superior sagittal sinus thrombosis, Cortical veins thrombosis, Anticoagulation therapy

INTRODUCTION

Cerebral venous sinus thrombosis (CVST) is a rare but potentially life-threatening condition characterized by the formation of blood clots in the cerebral veins and sinus. This condition can lead to significant disruption of venous blood flow and increased intracranial pressure (ICP), causing a variety of neurological symptoms.^[1,2] CVST can involve different venous sinuses within the brain, with the superior sagittal sinus (SSS) being the most commonly affected. The clinical presentation of CVST is highly variable, making diagnosis challenging and necessitating a high index of suspicion, especially in young patients presenting with unexplained neurological symptoms such as headaches, seizures, or focal neurological deficits. Given its rarity and diverse presentation, CVST requires prompt recognition and treatment to prevent long-term complications or mortality.^[1,3] This case report discusses a 16-year-old female who presented with acute neurological symptoms secondary to CVST, highlighting the diagnostic approach, management, and outcomes in this rare but serious condition.

CASE REPORT

A 16-year-old female had been referred to our hospital after experiencing a 12-day history of persistent headaches. The headache had been described as intense, stabbing, and sharp, occasionally spreading from the eyes to the back of the head, and had been accompanied by dizziness. Eleven days before admission, the patient had suffered a generalized tonic-clonic seizure lasting approximately 2 min, followed by unconsciousness. During this period, she had experienced ten episodes of generalized seizures, each lasting several minutes. After the seizures had subsided, she had felt lethargic and fallen asleep. Upon regaining consciousness, she had exhibited motor aphasia, which was characterized by difficulty expressing words despite understanding instructions, as well as numbness and weakness on the right side of her body. She had initially been treated at a local hospital, where she had been diagnosed with status epilepticus and had received phenytoin 100 mg twice daily and piracetam 700 mg three times daily to control the seizures. Although the seizures had been managed effectively, the headache and neurological symptoms had persisted, prompting her referral to our facility for further evaluation. The patient had reported a history of

*Corresponding author: Muhammad Yunus Amran, Division of Interventional Neurology and Neuroendovascular Therapy, Department of Neurology, Faculty of Medicine, Hasanuddin University, Makassar, Indonesia. muhyunusamran@med.unhas.ac.id, yunusamran10@gmail.com

Received: 22 November 2024 Accepted: 19 December 2024 Epub ahead of print: 03 February 2025 Published: XXXXX DOI: 10.25259/JNRP_430_2024

This is an open-access article distributed under the terms of the Creative Commons Attribution-Non Commercial-Share Alike 4.0 License, which allows others to remix, transform, and build upon the work non-commercially, as long as the author is credited and the new creations are licensed under the identical terms. ©2025 Published by Scientific Scholar on behalf of Journal of Neurosciences in Rural Practice

fever two weeks before admission, which had resolved on its own. She had denied any prior use of oral contraceptives or a history of trauma, hypertension, diabetes, cardiovascular disease, or tuberculosis. On initial evaluation, she had been fully conscious (Glasgow Coma Scale E4M6V5) with motor aphasia, moderate right-sided weakness (muscle strength scale 4), and hyperreflexia in the right lower limb. Babinski and other pathological reflexes had been absent. Laboratory investigations had revealed elevated D-dimer levels (4.96 ng/mL) and raised liver transaminases: Serum glutamic oxaloacetic transaminase (132 U/L) and serum glutamic pyruvic transaminase (162 U/L), while coagulation studies, including prothrombin time, activated partial thromboplastin time, and international normalized ratio, had been normal.

The axial magnetic resonance imaging images of the brain findings [Figure 1] in this case provided clear evidence of CVST involving the SSS. On the axial T1-weighted (T1W), T2-weighted (T2W), T2-fluid-attenuated inversion recovery (T2-FLAIR), and diffusion-weighted imaging (DWI) sequences [Figure 1a], hyperintense signals were present in both parietal regions, particularly near the midline, indicating areas of venous congestion or ischemia due to impaired venous outflow. These changes were consistent with the involvement of the SSS, one of the brain's major venous structures. There was also a distinct hyperintense lesion in the right frontal lobe [Figure 1b], likely representing a subacute hemorrhage, which is a common complication of CVST resulting from elevated venous pressure and vessel

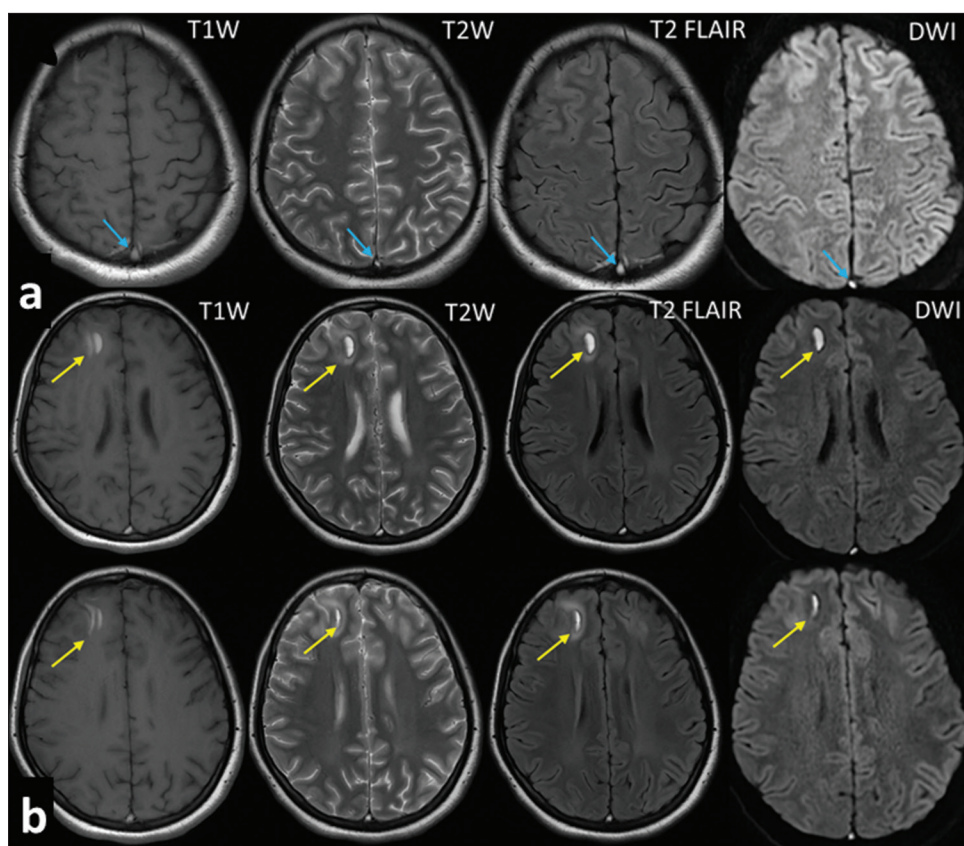


Figure 1: Axial MRI images of the brain: T1-weighted (T1W), T2-weighted (T2W), T2-FLAIR, and diffusion-weighted imaging (DWI) sequences in a patient with CVST. (a) The axial T1W, T2W, T2-FLAIR, and DWI sequences reveal hyperintense signals in the bilateral parietal regions (blue arrow), indicative of venous ischemia or infarction. These lesions are localized near the midline, suggesting involvement of the superior sagittal sinus, the most common site for CVST. The distribution and pattern of these hyperintensities are consistent with venous congestion or edema, resulting from impaired venous drainage due to thrombosis; (b) The axial T1W, T2W, T2-FLAIR, and DWI images also demonstrate a hyperintense region in the right frontal lobe (yellow arrow), likely representing a subacute hemorrhagic lesion secondary to CVST, characterized by crescent-shaped intracranial hemorrhage. In addition, the presence of bilateral hyperintense areas on the FLAIR sequence in the parietal regions further supports the diagnosis of venous congestion or ischemic changes, common complications associated with superior sagittal sinus thrombosis. MRI: Magnetic resonance imaging, CVST: Cerebral venous sinus thrombosis, FLAIR: Fluid-attenuated inversion recovery.

rupture. Additional bilateral hyperintense signals visible on the FLAIR images further suggested ischemic or congestive changes related to CVST.

The magnetic resonance venography (MRV) and magnetic resonance angiography (MRA) brain sequences [Figure 2] confirmed the diagnosis by showing a lack of normal blood flow in the SSS and cortical veins, indicative of thrombosis. These images together demonstrated the effects on the SSS and cortical veins, including venous obstruction, elevated ICP, and secondary ischemic and hemorrhagic brain injury. The combination of T1W, T2W, T2-FLAIR, DWI, MRV, and MRA imaging provided a comprehensive understanding of

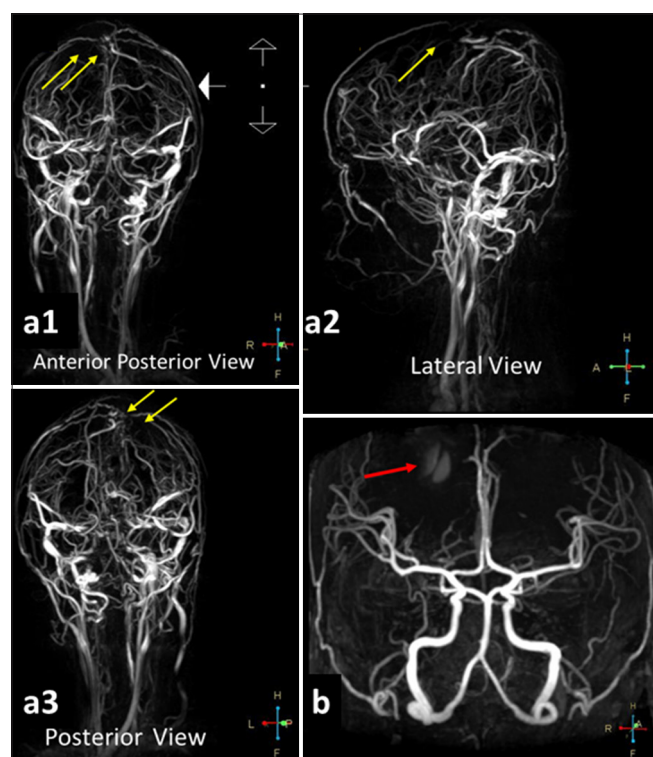


Figure 2: MRV and MRA brain sequences in a patient with CVST. (a1) The anterior-posterior view of the MRV demonstrates a segmental cut-off or occlusion in the superior sagittal sinus and cortical veins (yellow arrows), confirming the diagnosis of CVST; (a2) The lateral view of the MRV similarly shows a segmental cut-off or occlusion in the superior sagittal sinus and cortical veins (yellow arrow), further supporting the diagnosis of CVST; (a3) The posterior view of the MRV reveals a segmental cut-off or occlusion in the superior sagittal sinus and cortical veins (yellow arrows), confirming the presence of CVST; (b) The anterior cranial view of the MRA indicates contrast leakage (red arrow), confirming the presence of late subacute hemorrhage in the right frontal lobe accompanied by perifocal edema. This phenomenon is attributed to venous occlusion, which disrupts normal blood flow, leading to venous hypertension, edema, and ischemic changes in the affected cortical regions. MRI: Magnetic resonance imaging, CVST: Cerebral venous sinus thrombosis, MRA: Magnetic resonance angiography, MRV: Magnetic resonance venography.

the underlying pathology in this patient, underscoring the critical role of advanced imaging techniques in diagnosing and managing CVST.

To further assess the patient's condition, cerebral digital subtraction angiography [Figure 3] was performed, which revealed reduced blood flow to the SSS and bilateral cortical veins, particularly on the right side.

Based on the clinical, radiological, and angiographic findings, a diagnosis of CVST had been made. Treatment had included a subcutaneous injection of 2.5 mg of fondaparinux (anti-factor Xa) once daily, which was later transitioned to a direct anticoagulant on day 7. Additional supportive care had included analgesia with ketorolac 30 mg intravenously twice daily. The patient's headache had fully resolved by day 9 of treatment.

DISCUSSION

This case of a 16-year-old female with CVST highlights key clinical features and the complexity of managing the condition. Headache was the initial and dominant symptom, which is consistent with studies reporting that headaches occur in 60–90% of CVST cases. The character of the headache, often throbbing or pressure-like, can progress gradually over days and is typically linked to increased ICP. In this case, the persistence of headaches despite adequate seizure management aligns with findings from studies in Pakistan, India, and Turkey, where headache is frequently reported as the most prevalent symptom among CVST patients. Globally, the incidence of CVST is significantly higher in females, with studies consistently demonstrating a marked predominance among women, particularly those of reproductive age, with an average age commonly reported as between 36 and 39 years. Headache continues to be the most commonly reported clinical manifestation. On a global scale, CVST has an incidence rate of 2.62 cases/100,000 individuals, with hormonal influences such as pregnancy and contraceptive use serving as significant risk factors. These findings strengthen the understanding that headache is the predominant clinical feature of CVST, especially among female patients.^[1,3,4] Seizures, a common symptom of CVST, were also observed in this patient. Seizures often arise in patients with supratentorial hemorrhagic lesions or cortical vein thrombosis and are particularly common in the acute phase of CVST. In this case, the patient's imaging studies showed thrombosis in the SSS and cortical veins, supporting the pathophysiology linking seizures to this anatomical involvement. Early seizure activity is common, with reports showing early seizures in 44.3% of CVST patients and status epilepticus in up to 12.8%. The use of anticonvulsants, such as phenytoin in this case, is crucial for managing recurrent seizures.^[1,5] Aphasia, a focal neurological deficit, was another significant finding in this patient, emerging after the CVST diagnosis. Aphasia is often associated with thrombosis in the dominant hemisphere's cortical veins, particularly in the left lateral sinus, as was the

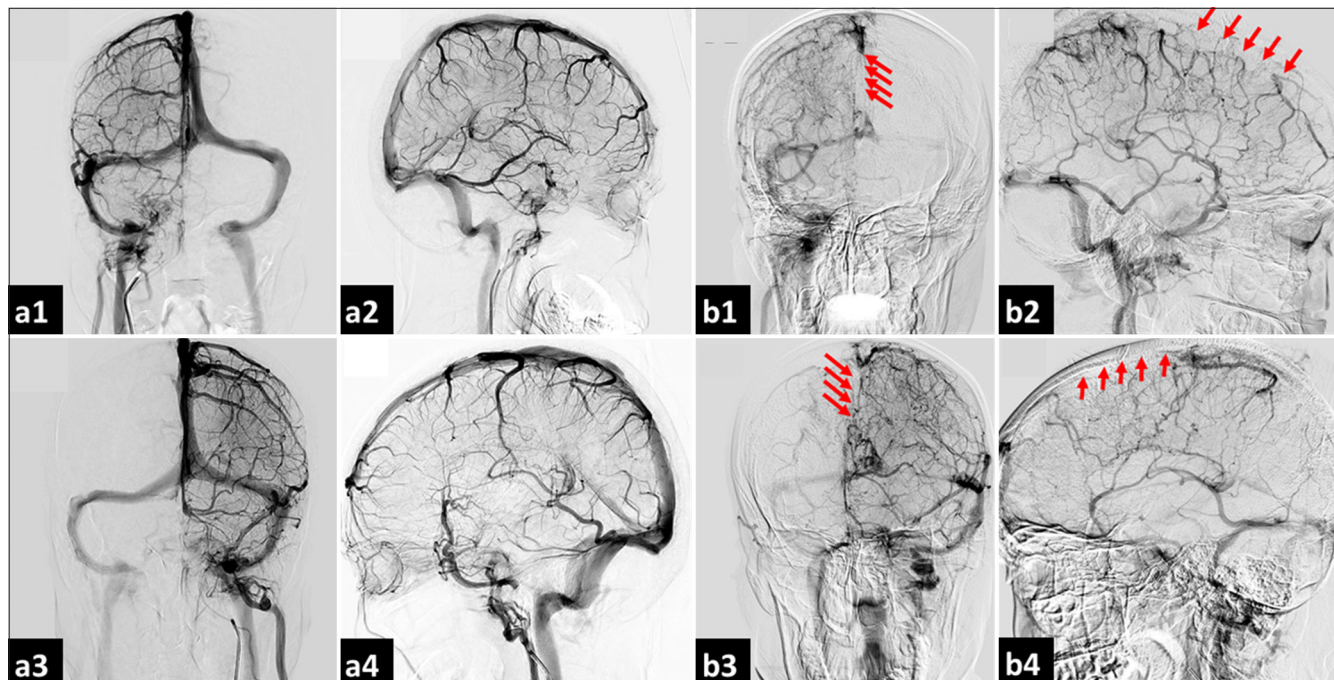


Figure 3: Cerebral digital subtraction angiography: Venous phase in a patient with CVST. (a1) Contrast injection from the right internal carotid artery (Rt-ICA) in the anterior-posterior view reveals a normal pattern of the cerebral venous sinus; (a2) The lateral view of contrast injection from the Rt-ICA also displays a normal pattern of the cerebral venous sinus; (a3) Contrast injection from the left internal carotid artery (Lt-ICA) in the anterior-posterior view shows a normal pattern of the cerebral venous sinus; (a4) The lateral view of contrast injection from the Lt-ICA similarly demonstrates a normal pattern of the cerebral venous sinus; (b1) Contrast injection from the Rt-ICA in the anterior-posterior view indicates reduced flow to the superior sagittal sinus and bilateral cortical veins, particularly on the right side, raising the suspicion of thrombosis in both the superior sagittal sinus and cortical veins (red arrows); (b2) The lateral view of contrast injection from the Rt-ICA corroborates the finding of reduced flow to the superior sagittal sinus and bilateral cortical veins, especially on the right side, suggesting possible thrombosis (red arrows); (b3) Contrast injection from the Lt-ICA in the anterior-posterior view reveals diminished flow to the superior sagittal sinus and bilateral cortical veins, predominantly on the right side, further indicating potential thrombosis (red arrows); and (b4) The lateral view of contrast injection from the Lt-ICA also shows reduced flow to the superior sagittal sinus and bilateral cortical veins, particularly on the right side, reinforcing the possibility of thrombosis in these regions (red arrows). CVST: Cerebral venous sinus thrombosis.

case in this patient. Literature suggests that aphasia occurs in 19–24% of CVST cases, and its presence in this patient further underscores the multifaceted neurological impact of CVST.^[1,6]

In addition, intracerebral hemorrhage (ICH) developed in this patient, a complication known to affect 30–40% of CVST cases. ICH in the setting of CVST is associated with a worse prognosis and is linked to increased venous pressure and compromised neurovascular integrity. The rupture of dilated veins due to CVST can result in hemorrhagic transformation, as occurred in this case, where imaging showed a right frontal hematoma. This complication raises concerns for long-term morbidity and mortality.^[4,7] Previous studies indicate that D-dimer serves as a sensitive diagnostic tool for excluding CVST in low-risk patients. Notably, a meta-analysis revealed a high negative predictive value for D-dimer levels in patients presenting with isolated headaches suspected of having CVST.^[8,9]

In our case, the initial D-dimer level of 4.96 ng/mL, followed by a decrease to 2.78 ng/mL after treatment, underscores

the utility of this biomarker not only in confirming the diagnosis but also in monitoring the effectiveness of anticoagulation therapy in a patient without traditional risk factors for CVST. This highlights the importance of D-dimer testing in assessing patients with unexplained headache symptoms, reinforcing its role in clinical decision-making.^[10,11]

The management of CVST in this patient followed established guidelines. Anticoagulation therapy is a mainstay of CVST treatment, even in the presence of ICH. In this case, fondaparinux, a factor Xa inhibitor, was administered subcutaneously, followed by oral anticoagulation. According to the European Stroke Organization and American Heart Association/American Stroke Association guidelines, anticoagulation should be continued for 3–6 months in provoked cases and 6–12 months in unprovoked cases. Warfarin was chosen for long-term management in this patient, as direct oral anticoagulants and factor Xa inhibitors are not the first-line choice for CVT according to current guidelines.^[1,10,12]

Table 1: Summary of clinical presentations, imaging findings, treatment, and outcomes in recent case reports of cerebral venous sinus thrombosis (CVST).

No	Author (s)	Year	Patient demographics	Clinical presentation	Imaging findings	Treatment	Outcome
1.	Sun <i>et al.</i> ^[13]	2018	Female, 57-year-old	Headache, nausea, vomiting, incomplete motor aphasia, right hemihypalgesia, later developed seizures	CT: Linear high-density images in parietal, frontal, occipital lobes; MRA, MRV confirm sagittal sinus thrombosis	Dehydration therapy, no anticoagulants or thrombolytics	Patient improved with mild right-sided weakness and non-fluent aphasia; no recurrence of thrombosis
2.	Katwal <i>et al.</i> ^[4]	2024	Male, 30-year-old	Sudden onset right-sided weakness, 5-day history of severe headache, nausea, vomiting, no prior medical history, reduced muscle strength, right-sided paresthesia, difficulty comprehending language	Non-contrast CT: hypodense lesion in left parietal lobe, hemorrhage, mass effect. MRI venography confirmed thrombosis in superior sagittal sinus, left vein of Trolard, and parietal cortical veins	Low-molecular-weight heparin for 10 days, followed by oral vitamin K antagonists	Clinical improvement, regained motor function, minimal residual symptoms, good recovery with physiotherapy. Declined follow-up MRI due to financial reasons
3.	Casanova <i>et al.</i> ^[14]	2023	Female, 17-year-old	Severe left-sided headache, nausea, vomiting, confusion, somnolence, white coat hypertension, history of polyarticular joint pain, malar rash	CT: left parietotemporal intraparenchymal hemorrhage, vasogenic edema, partial collapse of the left side ventricular system. MRV: absence of filling of the left transverse sinus	Intravenous antihypertensive medication, methylprednisolone, hydroxychloroquine, calcitriol, erythropoietin, anticoagulation (heparin), cyclophosphamide, renal replacement therapy due to acute kidney failure	Extubated without complications, improvement in symptoms, discharged on day 20. Cause of CVT determined to be systemic lupus erythematosus and antiphospholipid syndrome
4.	Chen and Diaz ^[15]	2024	Male, 66-year-old	Sudden severe headache, impaired consciousness, right-sided motor preference	CT: Empty delta sign, intraparenchymal hemorrhage, subarachnoid hemorrhage, venogram for AVM suspicion	Mannitol, nimodipine, high-dose atorvastatin, anticoagulation with rivaroxaban	Symptoms improved with treatment; anticoagulation continued
5.	Al Zahrani <i>et al.</i> ^[16]	2019	Female, 24-year-old, Pregnant	Generalized tonic-clonic seizure, unclear speech, eye-rolling, salivation	CT venogram: Superior sagittal sinus thrombosis, frontal lobe hemorrhage	LMWH, levetiracetam	Full recovery, continued LMWH; levetiracetam discontinued after 2 months

(Contd...)

Table 1: (Continued).

No	Author (s)	Year	Patient demographics	Clinical presentation	Imaging findings	Treatment	Outcome
6.	Nie <i>et al.</i> ^[17]	2015	Female, 27-year-old, Pregnant	Acute severe headache, slurred speech, conscious but afebrile	CT: Temporal hemorrhage, MRV: Left transverse sinus and sigmoid sinus thrombosis, DSA confirmed	Mannitol, LMWH followed by warfarin	Hemorrhage regressed; patient transitioned to warfarin therapy
7.	Delahanty and Parker ^[18]	2019	Female, 31-year-old	Decreased consciousness, nausea, vomiting, urinary incontinence	CT revealed frontal lobe hemorrhage	Managed with decompressive craniectomy, anticoagulation, and post-operative heparin infusion.	Patient improved and resumed normal activities.
8.	AlQahtani <i>et al.</i> ^[19]	2024	Male, 33-year-old, history of IgA nephropathy, mitral valve replacement	Severe headaches, loss of consciousness, convulsions, subdural hematoma, suspected systemic vasculitis, history of mouth ulcers, family history of lupus	CT: Subdural hematoma, ischemic infarction in right frontal-parietal and temporal lobes, cerebral venous thrombosis; MRI/MRA/MRV: Bilateral acute infarcts with bleeding, SSS thrombosis	Heparin infusion (switched to fondaparinux due to HIT), plasma exchange, IV methylprednisolone, IV hydrocortisone, acetazolamide, levetiracetam, CRRT, EVD insertion for intraventricular hemorrhage	Significant clinical progress, extubated, tracheostomy, new left parieto-occipital hemorrhage, occasional sedation for anger management, responding to basic commands
9.	Patil and Faruqi ^[20]	2024	Male, 23-year-old, Indian	Altered consciousness, weakness, generalized tonic-clonic seizures	CT showed superior sagittal sinus abnormalities and evidence of CVST	Treated with LMWH, levetiracetam, and additional anticonvulsants.	Outcome not specified; ongoing treatment.
10.	Shabbir <i>et al.</i> ^[21]	2023	Male, 44-year-old with hypertension and dyslipidemia	Collapsed in the CT scanner room during duty, experienced abrupt seizure-like activity, followed by postictal confusion	Non-contrast CT showed two small left parietal foci of intraparenchymal hemorrhage without ventricular extension or midline shift	Initially treated with heparin infusion; transitioned to oral anticoagulation after 2 days of treatment, seizure prophylaxis with phenytoin, and supportive care	Discharged after a week in the ICU with a planned follow-up in the Neurology clinic; unclear etiology of CVST, further outpatient workup planned
11.	Torere B E, <i>et al.</i> ^[9]	2023	Male, 34-year-old with a history of methamphetamine abuse, intravenous drug use, and asthma	Right chest wall pain and swelling, pancytopenia, right-sided numbness, dysarthria, headaches, seizures, neurological decline	CT: Right parietal and left frontal hematomas, cerebral venous thrombosis (SSS and bilateral cortical veins), vasogenic edema, hemorrhagic venous infarcts	IV antibiotics, incision and drainage of abscess, chemotherapy for ALL (CALGB10403), palliative care, IV heparin, argatroban, switched to enoxaparin, filgrastim, Hyper CVAD, blinatumomab	Improved with residual left-sided weakness and slurred speech, complete remission of ALL, referred for stem cell transplantation

CT: Computed tomography, MRI: Magnetic resonance imaging, MRA: Magnetic resonance angiography, MRV: Magnetic resonance venography, CVT: Cerebral venous thrombosis, CVST: Cerebral venous sinus thrombosis, LMWH: Low-molecular-weight heparin, SSS: Sinus sagittal superior, DSA: Digital subtraction angiography, CVAD: Cyclophosphamide, vincristine, adriamycin, and dexamethasone, ALL: Acute lymphoblastic leukemia, AVM: Arteriovenous malformation

Table 1 summarizes several cases of CVST based on their clinical presentations, imaging findings, therapy, and outcomes.

CONCLUSION

This case underscores the critical elements involved in the diagnosis and management of CVST, emphasizing the interplay between clinical evaluation, imaging diagnostics, and therapeutic interventions. The patient presented with hallmark features of CVST, including persistent headache, seizures, and focal neurological deficits, which are well-documented manifestations of this condition. The occurrence of intracerebral hemorrhage, while complicating the clinical scenario, did not preclude the initiation of anticoagulation therapy, which remains the foundation of CVST treatment. The integration of anticoagulation with adjunctive measures for symptomatic management, such as analgesics for headache and antiepileptics for seizure control, resulted in significant clinical improvement, highlighting the efficacy of current evidence-based management strategies. This case emphasizes the necessity of prompt recognition, the use of advanced imaging modalities for accurate diagnosis, and strict adherence to established treatment protocols to achieve optimal clinical outcomes in patients with CVST.

Authors' contributions

MYA: Conceptualization, investigation, writing-original draft, writing-review, editing, and supervision. YAF: Conceptualization, investigation, writing-review, and editing.

Acknowledgments

Not applicable.

Ethical approval

The Institutional Review Board approval is not required.

Declaration of patient consent

The authors certify that they have obtained all appropriate patient consent.

Financial support and sponsorship

Nil.

Conflicts of interest

There are no conflicts of interest.

Use of artificial intelligence (AI)-assisted technology for manuscript preparation

The authors confirm that there was no use of artificial intelligence (AI)-assisted technology for assisting in the writing or editing of the manuscript and no images were manipulated using AI.

REFERENCES

1. Saposnik G, Bushnell C, Coutinho JM, Field TS, Furie KL, Galadanci N, *et al.* Diagnosis and management of cerebral venous thrombosis: A scientific statement from the American Heart Association. *Stroke* 2024;55:e77-90.
2. Furie KL, Cushman M, Elkind MS, Lyden PD, Saposnik G, American Heart Association/American Stroke Association Stroke Council Leadership. Diagnosis and management of cerebral venous sinus thrombosis with vaccine-induced immune thrombotic thrombocytopenia. *Stroke* 2021;52:2478-82.
3. Amalia L. D-dimer level associated with amount of sinus involvement using digital subtraction angiography on cerebral venous thrombosis patients. *J Blood Med* 2023;14:303-8.
4. Katwal S, Suwal S, Lamichhane S, Bhusal A, Yogi TN. Cerebral venous sinus thrombosis with hemorrhagic infarct: A rare presentation in a risk-defying male patient. *Radiol Case Rep* 2023;19:153-7.
5. Ordieres-Ortega L, Moragón-Ledesma S, Demelo-Rodríguez P. Cerebral venous thrombosis. *Rev Clin Esp (Barc)* 2024;224:237-44.
6. Munteanu G, Motoc AG, Dan TF, Gogu AE, Jianu DC. Aphasic syndromes in cerebral venous and dural sinuses thrombosis-a review of the literature. *Life (Basel)* 2022;12:1684.
7. Xu L, Fu G. Cerebral venous thrombosis presented with symmetrical crescent-shaped intracranial hemorrhage in alcoholic liver disease: Case reports. *Medicine (Baltimore)* 2024;103:e37441.
8. Moraes Junior AA, Conforto AB. Cerebral venous thrombosis. *Arq Neuropsiquiatr* 2022;80:53-9.
9. Torere BE, Weigold J, Aiwuyo HO, Alugba G, Ntukidem O, Tan J. Diagnostic and therapeutic challenges of concurrent intracranial hemorrhage and cerebral venous thrombosis in a patient with acute lymphoblastic leukemia: A case report and literature review. *Cureus* 2023;15:e37482.
10. Tardy B, Tardy-Poncet B, Viallon A, Piot M, Garnier P, Mohamedi R, *et al.* D-dimer levels in patients with suspected acute cerebral venous thrombosis. *Am J Med* 2002;113:238-41.
11. Smith E, Kumar V. BET 1: Does a normal D-dimer rule out cerebral venous sinus thrombosis (CVST)? *Emerg Med J* 2018;35:396-7.
12. Wasay M, Khan M, Rajput HM, Farooq S, Memon MI, AlRukn SA, *et al.* New oral anticoagulants versus warfarin for cerebral venous thrombosis: A multi-center, observational study. *J Stroke* 2019;21:220-3.
13. Sun J, He Z, Nan G. Cerebral venous sinus thrombosis presenting with multifocal intracerebral hemorrhage and subarachnoid hemorrhage: A case report. *Medicine*

- (Baltimore) 2018;97:e13476.
14. Casanova Rivera MF, Ligua Duque NB, Moreno Veloz EA, Casanova Rivera PS. Cerebral venous thrombosis in a 17-year-old female patient: A case report. *Cureus* 2023;15:e42384.
 15. Chen FG, Diaz JB. Cerebral venous sinus thrombosis presenting as intracerebral hemorrhage and subarachnoid hemorrhage: A case report. *J Med Univ Santo Tomas* 2024;8:1371-6.
 16. Al Zahrani AM, Sheikh RA. Cerebral Venous sinus thrombosis with an intracranial haemorrhage: A case report. *Open Access Maced J Med Sci* 2019;7:1029-31.
 17. Nie Q, Guo P, Ge J, Qiu Y. Cerebral venous sinus thrombosis with cerebral hemorrhage during early pregnancy. *Neurosciences (Riyadh)* 2015;20:48-51.
 18. Delahanty LF, Parker TG. A case of central venous sinus thrombosis in a young woman. *Clin Pract Cases Emerg Med* 2019;3:345-8.
 19. AlQahtani BG, Kajtazi N, Aljaidi HK. Multifaceted cerebral venous thrombosis with extensive intra-cerebral hemorrhage in a young man with mitral valve replacement due to thrombosis and IgA nephropathy: A challenging case report from Saudi Arabia. *Cureus* 2024;16:e60016.
 20. Patil RS, Faruqi AA. A case report of simultaneous intracranial hemorrhage and cerebral venous sinus thrombosis in a young Indian male: Diagnostic and therapeutic challenges. *Cureus* 2024;16:e55642.
 21. Shabbir T, Hunsucker R, Martin D, Shabbir Z, Abou-El-Hassan H, Salahuddin T. A 44-year-old male with cerebral venous sinus thrombosis. *Cureus* 2023;15:e36974.

How to cite this article: Amran MY, Fitrah YA. Crescent-shaped intracranial hemorrhage in cerebral venous sinus thrombosis: A case report and review of literature. *J Neurosci Rural Pract.* doi: 10.25259/JNRP_430_2024