

Hansen's disease and HIV coinfection with facial nerve palsy

Nidhi Yadav, Sumit Kar, Bhushan Madke, Nitin Gangane¹

Departments of Dermatology, Venereology, Leprosy and ¹Pathology, Mahatma Gandhi Institute of Medical Sciences, Wardha, Maharashtra, India

ABSTRACT

There are very few published reports of HIV leprosy co infection in India in spite of having a large burden of both leprosy and HIV. Herein we are reporting a case of co-infection of Hansen's disease and HIV with facial nerve palsy.

Key words: Co infection, Hansen's disease, immune reconstitution inflammatory syndrome

Introduction

There is a declining trend in the global burden of leprosy, but still there are 15 countries in Asia and Africa including India that account for 94% of the newly detected cases globally.^[1] Both human immunodeficiency virus (HIV) and leprosy are associated with social stigma. Leprosy can manifest as immune reconstitution inflammatory syndrome (IRIS) in HIV-infected individuals.^[1] India accounts for not only half of the world's leprosy cases but it also has the third largest burden of HIV-infected individuals.^[2] There are very few published reports of HIV-leprosy co infection in India in spite of having a large burden of both leprosy and HIV.

Case Report

We are reporting a case of a 44-year-old immuno compromised male patient with Hansen's disease with right facial nerve palsy of lower motor neuron type.

This patient was taking highly active antiretroviral therapy (HAART) (lamivudine, zidovudine and efavirenz) since past 3 years and presented with red

raised lesions over the right side of face, right foot and left hand over the past 6 months. He was also not able to close his right eye completely. Cutaneous examination revealed multiple erythematous, edematous anesthetic plaques of varying size on right side of face, right foot and left hand. His right supra orbital nerve was thickened and non-tender [Figure 1]. Motor examination showed wasting of the thenar and hypothenar muscle group and severe weakness of small muscles of both hand. Cranial nerve examination showed right facial nerve palsy in the form of lagophthalmos [Figure 2]. His slit skin smear for AFB was negative and ESR was 30 mm at the end of 1 hour. His pre-HAART CD4 count was 187 cells/mm³ (July 2010) that had improved to 399 cells/mm³ (June 2013) after receiving anti-retroviral drugs. Histology of skin biopsy showed features suggestive of tuberculoid Hansen's disease [Figures 3 and 4]. He has been prescribed WHO-MDT-multi-bacillary and advised regarding eye care. He was referred to eye surgeon for tarsorrhaphy to prevent exposure keratitis.

Discussion

Clinical presentation of Hansen's disease mainly depends on the host response to the organism. Those with good cellular immunity presents with few skin lesion and few or no bacilli on slit skin smear. While those with poor cellular immunity tends to present with diffuse skin involvement in form of plaques and nodules.

The natural course of leprosy and HIV coinfection is not clearly understood. Till date there

Access this article online

Quick Response Code:



Website:

www.ruralneuropractice.com

DOI:

10.4103/0976-3147.150296

Address for correspondence:

Prof. Sumit Kar, Department of Dermatology, Venereology and Leprosy, Mahatma Gandhi Institute of Medical Sciences, Sewagram - 442 102, Wardha, Maharashtra, India. E-mail: karmgims@gmail.com

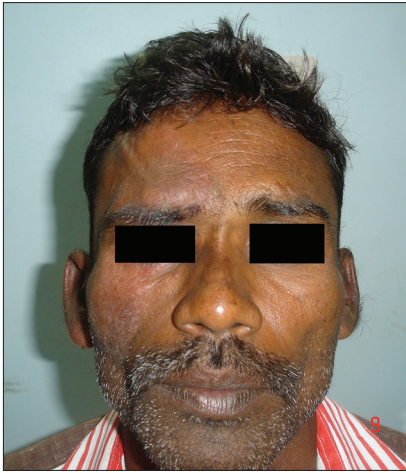

Figure 1: Thickened right supra orbital nerve

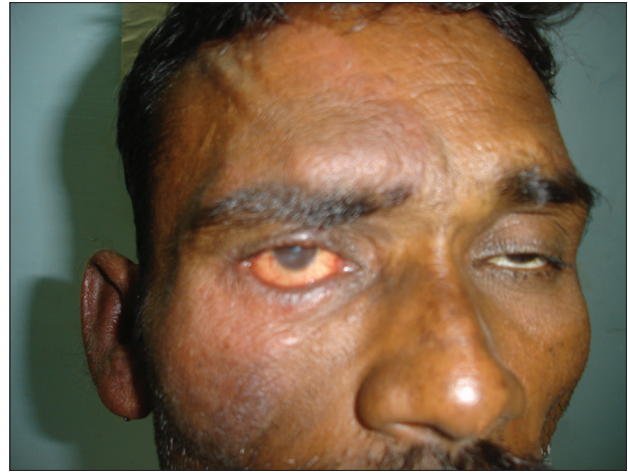

Figure 2: Lagophthalmos of right eye

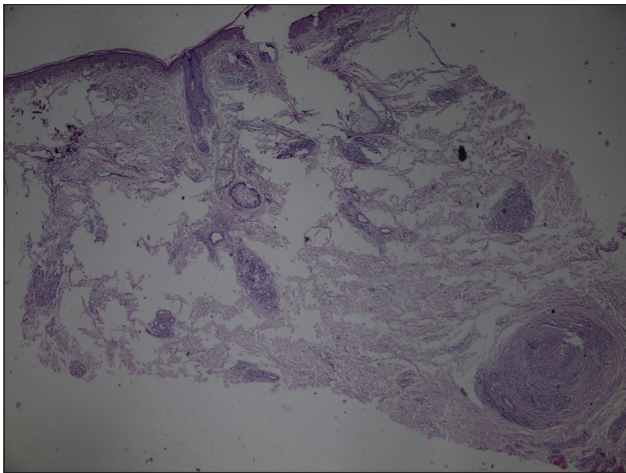


Figure 3: Histopathology slide showing epithelioid cell granuloma with numerous lymphocytes (Magnification x20)

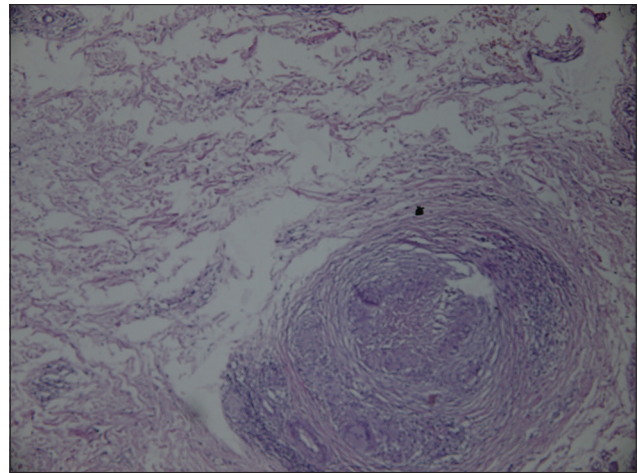


Figure 4: Histopathology slide showing epithelioid cell granuloma with numerous lymphocytes (Magnification x40)

has been no evidence which shows that HIV increases susceptibility to leprosy infection or has any effect on its pathogenesis.^[3] On the contrary, there are reports of activation of subclinical *M. Leprae* infection and exacerbation of existing leprosy lesions after initiation of HAART.^[4] We expect the lepromatous leprosy type to be present in cases of HIV and leprosy co infection but this was not found in the follow up studies. On the contrary, irrespective of the baseline T-lymphocyte count, tuberculoid form of leprosy was reported in the majority of these cases.^[5,6]

Our patient was on HAART over the past 3 years and his patches exacerbated after 32 months of starting HAART. We hypothesize that in our case the subclinical, unnoticeable leprosy patches became evident after restoration of the immune system by HAART. This hypothesis is supported by Couppie, *et al.* They determined the adjusted hazard ratio for a new diagnosis

of leprosy in those receiving HAART for 3 months or more over HIV-infected untreated patients to be 18.5 (95% CI: 1.6-217; $P=0.02$).^[7] Hence, the exacerbations or reactions of leprosy in those coinfecting with HIV can occur due to many possibilities such as IRIS. Secondly it can occur independently as a natural course of disease and thirdly HAART may unmask the underlying subclinical infections.

References

1. Vinay K, Smita J, Nikhil G, Neeta G. Human immunodeficiency virus and leprosy coinfection in Pune, India. *J Clin Microbiol* 2009;47:2998-9.
2. Shelburne SA 3rd, Hamill RJ. The immune reconstitution inflammatory syndrome. *AIDS Rev* 2003;5:67-79.
3. Available from: http://www.data.unaids.org/pub/EPISlides/2007/071119_epi_pressrelease_en.pdf. [Last accessed on 2008 Mar 13].
4. Rao GR, Amareswar A, Sandhya S. Can highly active antiretroviral therapy unmask leprosy? A case of type 1 lepra reaction in a HIV-seropositive patient. *Indian J Dermatol Venereol Leprol* 2012;78:101-3.

5. Sarno EN, Illarramendi X, Nery JA, Sales AM, Gutierrez-Galhardo MC, Penna ML, *et al.* HIV-M. leprae interaction: Can HAART modify the course of leprosy? Public Health Rep 2008;123:206-12.
6. Sampaio EP, Caneshi JR, Nery JA, Duppre NC, Pereira GM, Vieira LM, *et al.* Cellular immune response to Mycobacterium leprae infection in human immunodeficiency virus-infected individuals. Infect Immun 1995;63:1848-54.
7. Couppié P, Domergue V, Clyti E, El Guedj M, Vaz T,

Sainte-Marie D, *et al.* Increased incidence of leprosy following HAART initiation: A manifestation of the immune reconstitution disease. AIDS 2009;23:1599-600.

How to cite this article: Yadav N, Kar S, Madke B, Gangane N. Hansen's disease and HIV coinfection with facial nerve palsy. J Neurosci Rural Pract 2015;6:228-30.

Source of Support: Nil. **Conflict of Interest:** None declared.