



Brief Report

Reverse Y stenting in the management of vertebrobasilar junction fenestrated aneurysm: A novel technique

Manoj Kumar Nayak¹, Biswajit Sahoo¹, Anshu Mahajan², Suprava Naik¹, Nerbadyswari Deep (Bag)¹, Biswamohan Mishra³, Chinmaya Dash⁴

¹Department of Radiodiagnosis, All India Institute of Medical Sciences, Bhubaneswar, Odisha, ²Department of Interventional Neuroradiology, Medanta The Medicity, Gurgaon, Haryana, ³Department of Neurology, All India Institute of Medical Sciences, New Delhi, ⁴Department of Trauma and Emergency, All India Institute of Medical Sciences, Bhubaneswar, Odisha, India.

ABSTRACT

Fenestrated aneurysm at vertebrobasilar junction (VBJ) is very rare and can occur due to non-fusion of longitudinal neural axis forming basilar artery in the early stage of embryonic life. Due to defects in tunica media and weakness in its wall, these fenestrations are more likely to develop an aneurysm. Various treatment strategies are required for the management of these types of aneurysms including simple coiling, stent-assisted coiling, balloon remodeling technique, and more recently kissing flow diverters. Herein, we report the case of ruptured fenestrated VBJ aneurysm which was managed successfully with novel reverse Y stenting with coiling.

Keywords: Vertebrobasilar fenestration aneurysm, Fenestrated aneurysm in a basilar artery, Braided stent, Y stenting, Reverse Y stenting

INTRODUCTION

Vertebrobasilar junction (VBJ) fenestration is a rare embryological variation with an incidence of 0.3–5.26% in autopsy series and 0.1–1.9% in angiography series.^[1] Aneurysms associated with basilar artery fenestration were found in approximately 7% of cases while a higher incidence of aneurysms was observed at VBJ fenestration in approximately 35% of cases.^[2] Surgical access to VBJ aneurysms (VBJAs) is difficult and complex in local anatomy due to the presence of brainstem perforators and cranial nerves. There is also an increased chance of brainstem infarct and cranial nerve deficits in surgical intervention.^[3] Hence, endovascular treatment is the chosen mode of treatment with reasonably good outcomes.^[4] Few conventional methods were published in the literature where these VBJAs were managed with simple coiling, stent-assisted coiling, parent vessel occlusion (PAO), and more recently flow diverter (FD).^[3–6] Herein, we report a case of ruptured VBJA, treated by reverse Y stenting with coiling in a middle-aged female.

CASE REPORT

A 34-year-old female presented with sudden onset severe headache with loss of consciousness for 15 min 15 days

back. Magnetic resonance imaging (MRI) showed T2W hypointense flow void in the anterior pontomedullary cistern with mass effect over the lower pons and magnetic resonance angiography showed VBJA [Figure 1a and b]. Subsequently, digital subtraction angiography (DSA) with 3D rotational angiography showed two fenestrated aneurysms: Larger one filled from both fenestrated limbs and smaller one from the left limb of fenestration [Figure 1c and d]. Pseudobulbe was seen in the superior aspect of the larger aneurysm. As the nature of the complexity of the aneurysms, one braided stent in each limb of fenestration in reverse Y manner to accommodate a single stent in the basilar artery with limited intra-aneurysmal coiling to have reduced mass effect over the brainstem. The patient was loaded with 180 mg ticagrelor and 300 mg aspirin, 2 h before the procedure. Endovascular therapy was performed through bilateral femoral access using a femoral 6F sheath under general anesthesia, subsequently heparin (100 IU/kg) was given through arterial sheath. 6F neurons (penumbra) were parked in the distal V2 segment of both vertebral arteries (VAs), and then, the left limb of the fenestration was crossed with headway 17 (MicroVention-Terumo, Aliso Viejo, CA, USA), 0.014-inch synchro microwire (Stryker Neurovascular, Fremont, CA, USA) and subsequently braided stent (LVIS EVO, MicroVention-

*Corresponding author: Chinmaya Dash, Department of Trauma and Emergency, All India Institute of Medical Sciences, Bhubaneswar, Odisha, India. dr.chinu.dash@gmail.com

Received: 31 July 2023 Accepted: 07 October 2023 Epub Ahead of Print: 31 October 2023 Published: 05 February 2024 DOI: 10.25259/JNRP_423_2023

This is an open-access article distributed under the terms of the Creative Commons Attribution-Non Commercial-Share Alike 4.0 License, which allows others to remix, transform, and build upon the work non-commercially, as long as the author is credited and the new creations are licensed under the identical terms. ©2024 Published by Scientific Scholar on behalf of Journal of Neurosciences in Rural Practice

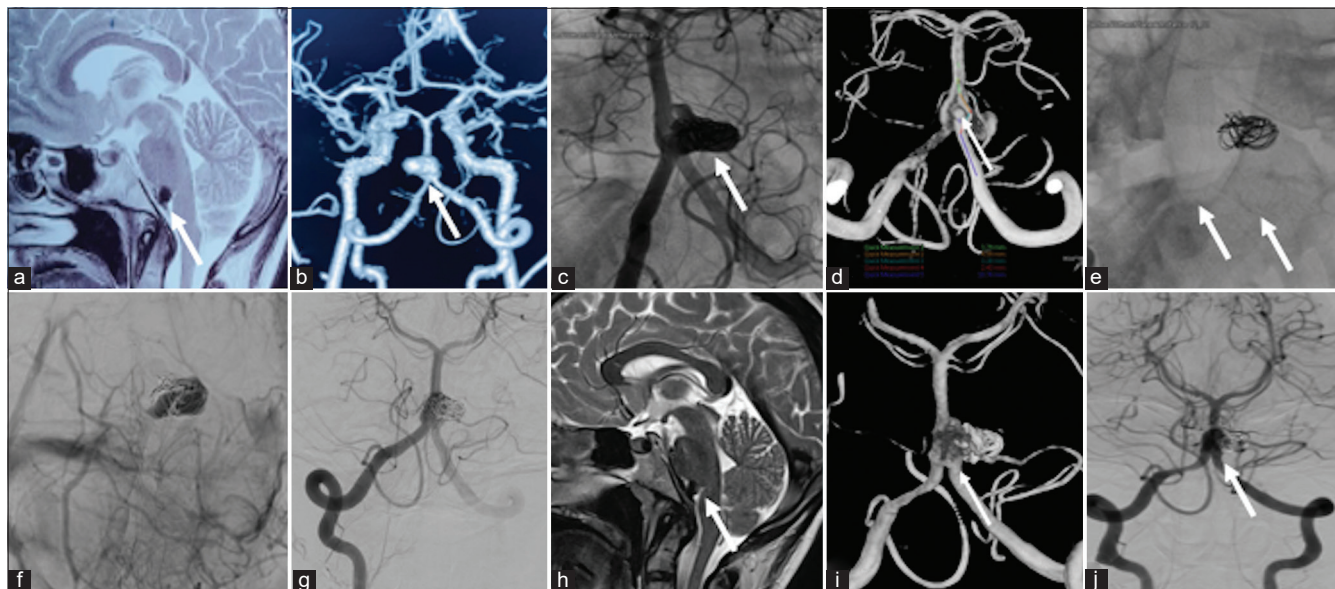


Figure 1: Magnetic resonance angiography (MRI) and digital subtraction angiography (DSA) images showing the aneurysm and reverse Y stenting at the vertebrobasilar junction (VBJ). (a-d) shows the Sagittal Brain MRI, MRI angiography and DSA respectively, depicting the aneurysm at the VBJ (white arrows). (e-g) depicts immediate post-treatment images showing the reverse Y stenting with coiling and stasis within the aneurysm (white arrows). (h) shows follow-up MRI and (i and j) shows followup DSA after 3 months depicting resolution of the small aneurysm in the left limb of the fenestration and no significant change in the size of the larger aneurysm (white arrow).

Terumo, Aliso Viejo, CA, USA) was placed from the left VA to distal end of the left limb of fenestration, just proximal to basilar artery junction. After the deployment of the device, its opening and apposition were ensured by navigating the microcatheter over the pusher wire. Immediate and interval control angiograms after 15 min were done to look for parent vessel, perforator patency, and clot formation within the stent. Subsequently, using the same microcatheter and microguide wire combination, a braided stent (LVIS EVO, MicroVention-Terumo, Aliso Viejo, CA, USA) was parked in the mid-basilar artery, distal to the joining of the fenestration. Then, using headway duo (MicroVention-Terumo, Aliso Viejo, CA, USA) and 0.014-inch synchro microwire (Stryker Neurovascular, Fremont, CA, USA), undercoiling was done within the sac of the larger aneurysm. Then, LVIS EVO (MicroVention-Terumo, Aliso Viejo, CA, USA) was placed from the mid-basilar artery to the right VA through the right limb of the fenestration, producing a reverse Y configuration [Figure 1e-g]. Immediate and interval control angiograms after 15 min were done to look for parent vessel, perforator patency, and clot formation within the stent. Post-procedure angiogram left VA showed no filling of the small aneurysm with antegrade flow into the basilar artery. Final check angiography of the right VA showed significant stasis within the aneurysm with patent stent and distal intracranial vessels. Post-procedure, she was extubated without any new onset neurologic deficits. Dual antiplatelet medications (aspirin 75 mg od and ticagrelor 90 mg bd) were continued,

and she was discharged on the post-operative period day 6 without any neurodeficit. Steroid was further continued for 5 days to prevent the inflammatory edema and mass effect in the brainstem. Clinical follow-up after 1 month showed complete resolution of headache. Follow-up MRI and DSA after 3 months showed a mild reduction in size of the larger aneurysm and resolution of the small aneurysm in the left limb of the fenestration with stents and coils *in situ* [Figure 1h-j]. As the patient is presently asymptomatic, and minimal reduction in the size of the residual aneurysm, the next follow-up DSA is planned at 1 year to look for aneurysmal status. If aneurysm will increase in its size, there may be a need for telescoping of FDs or braided stents within the existing braided stents. If aneurysm will remain stable or reduced in its size, follow-up will be needed both clinically and angiographically at 6-month intervals. The schematic illustration of the morphology and interventional procedure of the lesion is depicted below [Figure 2].

DISCUSSION

Vertebrobasilar fenestration occurs due to defects in embryogenesis in early fetal life. In the early embryonic period around 5th week of gestation, basilar artery is formed by the fusion of the paired longitudinal neural arteries in the midline. Fenestration can occur due to the failure of fusion of these midline arteries, driven by various environmental or genetic factors.^[7] A higher incidence of VBJ fenestration aneurysms was observed, more likely due to absent tunica

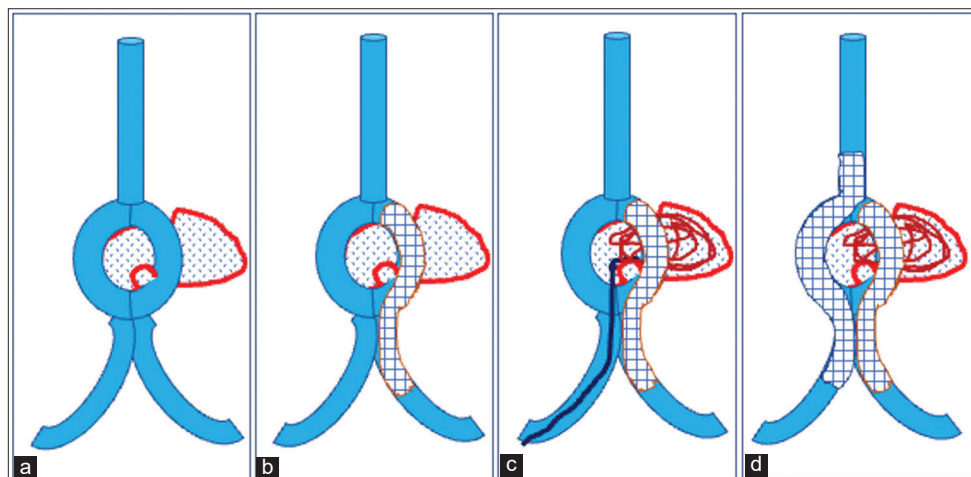


Figure 2: (a-d) The schematic illustration of the morphology of the lesion and interventional procedure step by step simulating reverse Y stenting.

media and local hemodynamic disturbances causing pressure effect on their wall. Van Rooij *et al.* classified fenestrated aneurysms into three types: Type I – aneurysm is situated at the proximal end of fenestration, Type II – aneurysm is situated at either of the limbs of fenestration, and Type III – fenestration and aneurysm are located on separate arteries.^[3] Essibayi *et al.* again renamed basilar fenestration limb aneurysms (BFLAs) where aneurysm involves one limb of fenestration, and VBJAs where aneurysms incorporating both BFLAs.^[8]

The higher rate of complications was associated with the microsurgical group in these aneurysms due to the complex morphology of these fenestrations, small perforators supplying the brainstem, close proximity to lower cranial nerves, and the difficulty of finding the optimum surgical field.^[9] In a systematic review by Essibayi *et al.*, they showed a higher post-operative complication rate (62.2%) in a microsurgical group as compared to endovascular therapy (8.3%).^[8]

Endovascular treatment in these aneurysms is the preferred mode of treatment with various techniques. In a study by Zhu *et al.*, they reviewed 71 patients with 79 VBJ fenestration aneurysms managed by coiling ($n = 56$), balloon remodeling technique ($n = 10$), stenting ($n = 10$), and parent artery occlusion with trapping ($n = 3$). In their study, they achieved 95.5% technical success rate, and good outcomes were observed in 78.9% of cases during the follow-up period.^[10] The incidence of complications such as ischemia, thrombus formation, relapse, and rebleeding was 9.9% in their observation.^[10]

Flow diversion is a relatively newer and more advanced technique and has the ability to preserve the perforators through a pressure gradient near the ostium, however, failed to preserve those perforators in small caliber limbs.^[8] Few

case reports were available for the treatment of fenestrated aneurysm in basilar artery with FD where kissing FD technique^[11] and crossing FD were used.^[4] Although stent-assisted coiling is less efficacious than FDs and PAO for complete obliteration of these aneurysms, it is effective in reconstructing BA and fenestrated limbs with good aneurysmal occlusion. Furthermore, this technique has a decreased incidence of stroke due to patent perforators and favorable angiographic outcomes, compared with other techniques.^[8] Similarly, in our case, braided stents were chosen due to reduced cost and decreased chance of perforator infarct.

The involvement of VAs in fenestration aneurysms does not have good post-operative angiographic outcomes (VBJAs 73.7% vs. BFLAs 83.9% for complete occlusion), whereas post-operative clinical outcomes were comparable in both these groups (87.5% vs. 90%).^[8] Those aneurysms which were ruptured in these groups required higher rate of retreatment rates than unruptured ones (11.5% vs. none). The decision regarding the complete obliteration of the aneurysm with VA sacrifice is based on multiple factors, such as the dominance of the VA, the size of the aneurysm, and the proximity of the perforator. In our case, small aneurysm in the left limb of fenestration was protected through one braided stent and larger aneurysm was secured using coils and the other limb of fenestration was through a braided stent resulting in a reverse Y configuration. This case is unique due to the presence of two braided stents, one from vertebral to basilar artery through the right limb of fenestration and another from the other vertebral to the end of left limb of fenestration in a reverse Y configuration. As the second braided stent is not in the basilar artery, there is a reduced chance of perforator infarct and no need to accommodate a second stent within the basilar artery like kissing FD technique. To the best of our knowledge, this is the index case of simultaneous positioning

of two braided stents in reverse Y manner with coiling of the aneurysm to treat a fenestrated aneurysm at VBJ.

CONCLUSION

The use of braided stents with coiling may be considered as an alternative approach to treat VBJ fenestrated aneurysm besides conventional coiling and flow diversion. Proper pre-treatment planning, a good understanding of the morphology, status of the perforators, and accurate placement of stents are required for a reverse Y stenting in VBJ fenestrated aneurysm. Due to the rare occurrence of these aneurysms and reverse Y stenting is first of its kind, future studies are needed for safety and efficacy of this procedure.

Ethical approval

Institutional Review Board approval is not required.

Declaration of patient consent

The authors certify that they have obtained all appropriate patient consent.

Financial support and sponsorship

Nil.

Conflicts of interest

There are no conflicts of interest.

Use of artificial intelligence (AI)-assisted technology for manuscript preparation

The authors confirm that there was no use of artificial intelligence (AI)-assisted technology for assisting in the writing or editing of the manuscript and no images were manipulated using AI.

REFERENCES

1. Bentura JE, Figueiredo EG, de Monaco BA, Teixeira MJ. Vertebrobasilar artery junction aneurysm associated with fenestration. *Arq Neuropsiquiatr* 2010;68:312-4.
2. Campos J, Fox AJ, Viñuela F, Lylyk P, Ferguson GG, Drake CG, *et al.* Saccular aneurysms in basilar artery fenestration. *AJNR Am J Neuroradiol* 1987;8:233-6.
3. Van Rooij SB, van Rooij WJ, Sluzewski M, Sprengers ME. Fenestrations of intracranial arteries detected with 3D rotational angiography. *AJNR Am J Neuroradiol* 2009;30:1347-50.
4. Gaikwad SB, Puneeth KT, Nadarajah J, Gupta MM. Complex basilar artery fenestration aneurysm successfully treated with single flow diverter using novel “crossing flow diverter technique”—a rare case report and review of literature. *Interv Neuroradiol* 2021;27:391-6.
5. Yoon SM, Chun YI, Kwon Y, Kwun BD. Vertebrobasilar junction aneurysms associated with fenestration: Experience of five cases treated with Guglielmi detachable coils. *Surg Neurol* 2004;61:248-54.
6. Albanese E, Russo A, Ulm AJ. Fenestrated vertebrobasilar junction aneurysm: Diagnostic and therapeutic considerations. *J Neurosurg* 2009;110:525-9.
7. Gupta V, Ahuja CK, Khandelwal N, Kumar A, Gupta SK. Treatment of ruptured saccular aneurysms of the fenestrated vertebrobasilar junction with balloon remodeling technique. A short case series and review of the literature. *Interv Neuroradiol* 2013;19:289-98.
8. Essibayi MA, Srinivasan VM, Madriñán-Navia HJ, Park MT, Scherschinski L, Catapano JS, *et al.* Management of basilar fenestration aneurysms: A systematic review with an illustrative case report. *J Neurointerv Surg* 2022;jnis-2022-019728;jnis-2022-019728.
9. Graves VB, Strother CM, Weir B, Duff TA. Vertebrobasilar junction aneurysms associated with fenestration: Treatment with Guglielmi detachable coils. *AJNR Am J Neuroradiol* 1996;17:35-40.
10. Zhu DY, Fang YB, Wu YN, Li Q, Duan GL, Liu JM, *et al.* Treatment of fenestrated vertebrobasilar junction-related aneurysms with endovascular techniques. *J Clin Neurosci* 2016;28:112-6.
11. Consoli A, Renieri L, Nappini S, Ricciardi F, Grazzini G, Scarpini G, *et al.* Endovascular treatment with ‘kissing’ flow diverter stents of two unruptured aneurysms at a fenestrated vertebrobasilar junction. *J Neurointerv Surg* 2013;5:e9.

How to cite this article: Nayak M, Sahoo B, Mahajan A, Naik S, Deep(Bag) N, Mishra B, *et al.* Reverse Y stenting in the management of vertebrobasilar junction fenestrated aneurysm: A novel technique. *J Neurosci Rural Pract.* 2024;15:126-9. doi: 10.25259/JNRP_423_2023