

Cerebral aspergillosis and acute myeloid leukemia

Georgios K Matis^{1,2}, Despoina Voultsinou³, Olga Chrysou², Theodoros Biribilis², Triantafillos Geroukis³

¹Department of Neuroradiology, University Hospital of Zurich, Zurich, Switzerland, ²Department of Neurosurgery, Democritus University of Thrace Medical School, Alexandroupolis, ³Department of Radiology, General Hospital of Thessaloniki "G. Papanikolaou", Thessaloniki, Greece

A 32-year-old man with no previous medical history presented with weight-loss, frequent rhinorrhagia, gum swelling, cephalalgia, fatigue, fever, and somnolence. Neither motor nor sensory deficits were noted. The patient quickly became comatose and required mechanical ventilation. The complete blood count and the peripheral blood smear provided results compatible with leukemia (leukocytosis of 17,600/mm³, neutrophils 14,000/mm³, platelets 151,000/mm³, hemoglobin 13 g/dl, Auer rods). Consequently, bone marrow and CSF (cerebrospinal fluid) samples were collected and analyzed with the aid of cytochemistry and flow cytometry. The sandwich enzyme-linked immunosorbent assay (ELISA), "PlateliaAspergillus" (Bio-Rad Laboratories, Marnes La Coquette, France) detected galactomannan antigens both in CSF and serum. Brain magnetic resonance imaging [Figure 1a-d] revealed a right frontal lesion with surrounding edema, which was ring enhancing after contrast administration. The DWI technique and the ADC values showed a limited diffusion [Figure 2a and b]. The diagnosis of cerebral aspergillosis was set. A stereotactic biopsy confirmed *Aspergillus fumigatus* as the cause of infection. Hyphae with branches of 45 degrees were seen (Grocott silver stain). The melanin-specific Masson-Fontana stain was used to exclude cerebral phaeohyphomycosis. Conidiophores of 8µm terminating in subclavate vesicles of 24 µm bearing uniseriate phialides were observed. The brain specimen was also inoculated on Sabouraud dextrose agar, and growth of white-dark grey colonies was observed. Amphotericin B (1 mg/Kg/day) was administered intravenously for a period of 6 weeks

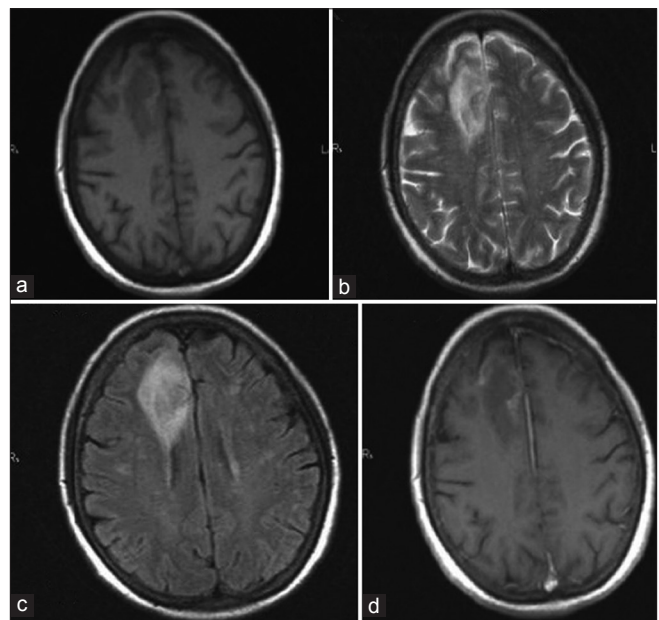


Figure 1: (a) T1: A hypo-intense lesion is depicted (right frontal lobe) (b) T2: A large area of edema is shown (c) FLAIR: The central portion exhibits a lower intensity signal as compared to the higher-signal perilesional area (angiogenic edema) (d) T1 postcontrast: Enhancement is illustrated

along with the liposomal formulation of daunorubicin (150 mg/m²) for 3 days. The new DWI images and the ADC map exhibited an increased diffusion [Figure 2c and d]. The primary focus of infection was not discovered. The patient failed to improve significantly, he did not regain consciousness and he eventually succumbed. An autopsy was not requested honoring the family's wishes.

This case represents one of a few reports depicting the presence of *Aspergillus* in the brain parenchyma in leukemia-harboring patients with the aid of modern magnetic resonance imaging techniques. Cerebral aspergillosis represents an opportunistic infection, which is commonly transmitted hematogenously.^[1] It also manifests as a vascular insult or/and an abscess.^[2]

Access this article online	
Quick Response Code:	Website: www.ruralneuropractice.com
	DOI: 10.4103/0976-3147.116459

Address for correspondence:

Dr. Georgios K. Matis, 10th Plattenstrasse (Room 1401), Zurich, CH-8032, Switzerland. E-mail: Georgios.Matis@uzh.ch

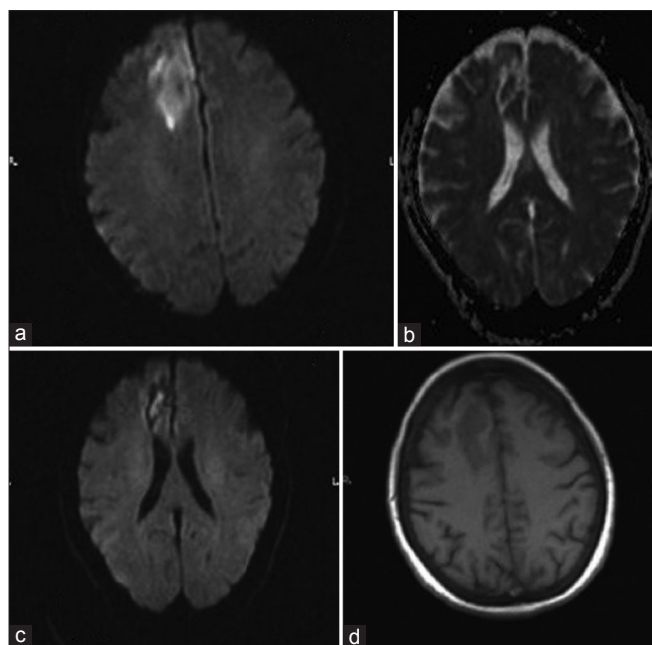


Figure 2: (a) DWI (diffusion-weighted imaging) (b-value: 1,000): High signal of the lesion (diffusion is restricted) (b) ADC (apparent diffusion coefficient) values show a limited diffusion (values ranging between 0.45 and $0.65 \text{ mm}^2/\text{s} \cdot 10^{-3}$) (c) Same patient, 6 weeks later: DWI (b-value: 1,000): High signal of the central part of the lesion (target sign) (d) Same patient, 6 weeks later: ADC values show an increased diffusion (values ranging between 1.12 and $1.2 \text{ mm}^2/\text{s} \cdot 10^{-3}$)

CT has always been the first line of evaluation but MRI still remains the method of choice due to its high sensitivity.^[3,4] Additionally, diffusion techniques increase specificity,^[1,2] and can evaluate the patients'

response to specific antifungal treatments. The three major neuroimaging findings in cerebral aspergillosis include infarction areas, ring lesions (post-infarct abscess formation), and dural/vascular infiltration.^[5] Recognition of these patterns results in an effective treatment.^[4,5] The authors' scope was not only to draw the readership's attention to this rare fungal entity but also to raise awareness for the substantial help that new imaging modalities could provide in setting an accurate diagnosis for the benefit of the patient. Especially the absence or presence of restricted diffusion in the setting of brain fungal infections may be of great clinical utility.

References

1. Preckel MP, Mercatello A, Tognet E, Devaux Y, Archimbaud E, Fiere D, *et al.* Cerebral aspergillosis in immuno compromised patients. *Ann Fr Anesth Reanim* 1991;10:463-7.
2. Golin V, Sprovieri SR, Caçado JE, Daniel JW, Mimica LM. Aspergillosis of the central nervous system. *Sao Paulo Med J* 1996;114:1274-7.
3. Liapis K, Manaka K, Baltadakis I, Karakasis D. Cerebral aspergillosis. *Eur J Haematol* 2009;82:327-8.
4. O'Brien D, Lim CH, Farrell M, O'Marcaigh A, Rawluk D, Fitzpatrick F, *et al.* Invasive intracerebral fungal infection in a leukaemic patient. *Br J Neurosurg* 2012;26:423-5.
5. Gabelmann A, Klein S, Kern W, Krüger S, Brambs HJ, Rieber-Brambs A, *et al.* Relevant imaging findings of cerebral aspergillosis on MRI: A retrospective case-based study in immunocompromised patients. *Eur J Neurol* 2007;14:548-55.

How to cite this article: Matis GK, Voultsinou D, Chrysou O, Birbilis T, Geroukis T. Cerebral aspergillosis and acute myeloid leukemia. *J Neurosci Rural Pract* 2013, 4(Suppl 1):s134-5.
Source of Support: Nil. **Conflict of Interest:** None declared.