

Case Series

# Intracranial peripheral primitive neuroectodermal tumor presenting as neurosurgical emergency: A report of two cases

Debajyoti Datta<sup>1</sup>, Arunkumar Sekar<sup>1</sup>, V. G. Parameshwar<sup>1</sup>, Suvendu Purkait<sup>1</sup>, Sumit Bansal<sup>1</sup>

<sup>1</sup>Department of Neurosurgery, All India Institute of Medical Sciences, Bhubaneswar, Odisha, India.

## ABSTRACT

Ewing's sarcoma/peripheral primitive neuroectodermal tumor (ES/pPNET) belongs to the family of malignant small and blue round cell tumors. It usually occurs in children and young adults with 3/4<sup>th</sup> of the cases arising from bone and 1/4 from soft tissue. Here, we present two cases of intracranial ES/pPNET who presented with mass effect. Management consists of surgical excision followed by adjuvant chemotherapy. Intracranial ES/pPNETs are highly aggressive and rare malignancies, reported to comprise of 0.03% of all intracranial tumors. The most common genetic aberration associated with ES/pPNET is chromosomal translocation t(11,12)(q24;q12). Patients with intracranial ES/pPNETs may present in acute or delayed manner. The presenting symptoms and signs depend on the location of the tumor. Intracranial pPNET although slow growing, they are highly vascular and may present as neurosurgical emergencies due to mass effect. We have presented the acute presentation of this tumor and its management.

**Keywords:** Intracranial ES/pPNET, Neurosurgical emergency, Mass effect

## INTRODUCTION

Ewing's sarcoma/peripheral primitive neuroectodermal tumor (ES/pPNET) is a type of malignant small and blue round cell tumors. It usually occurs in children and young adults with 3/4<sup>th</sup> of the cases arising from bone and rest 1/4<sup>th</sup> from soft tissue.<sup>[1]</sup> Intracranial ES/pPNET mostly occurs due to metastasis from extracranial sites.<sup>[2]</sup> Primary intracranial ES/pPNET is rare with estimated incidence being 1% and most commonly arising from the dura.<sup>[3]</sup> Intracranial ES/pPNETs usually present with mass effect due to the tumor with neurological deficits depending on the tumor location. Here, we report two cases of intracranial ES/pPNET who presented as neurosurgical emergency with mass effect and had fatal outcome.

## CASE SERIES

### Case 1

A 55-year-old lady presented with complaints of moderate intensity left frontal headache for a fortnight with associated worsening in vision for the past 1 week. She had established papilledema and speech disturbances. Her headache worsened and she presented in altered sensorium. Magnetic resonance imaging of the brain showed that she had a lesion

in the left frontal region with mass effect. The lesion was T1 isointense and T2 hyperintense SOL with heterogeneous contrast uptake [Figure 1]. She underwent gross total excision of the tumor. The tumor was extra-axial, greyish white, firm in consistency, and mildly vascular with definite plane of cleavage present between tumor and normal brain parenchyma [Figure 1]. Histopathological examination was suggestive of ES/pPNET [Figure 2].

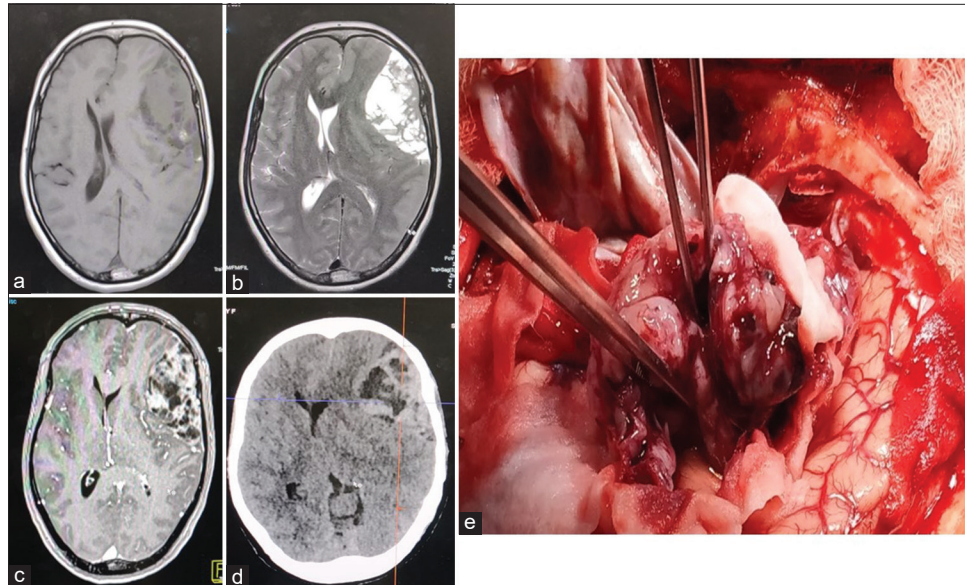
### Case 2

A 2-year-old girl presented with a history of swelling of the left orbit associated with proptosis for the past 2 years followed by loss of vision for 1 year. She had proptosis of the left eye along with 4 × 5 cm swelling extending laterally into the infratemporal fossa with corneal xerosis. She developed progressive drowsiness and presented with altered sensorium. Imaging showed a T1 isointense, T2 isohypointense, extra-axial, and contrast-enhancing SOL with diffusion restriction present in the left temporal region with invasion into the left orbit and infratemporal fossa [Figure 3]. USG abdomen and HRCT thorax did not show any lesion. She underwent excision of the tumor. The tumor was greyish-white, soft, friable, suckable, highly vascular, and with poor plane

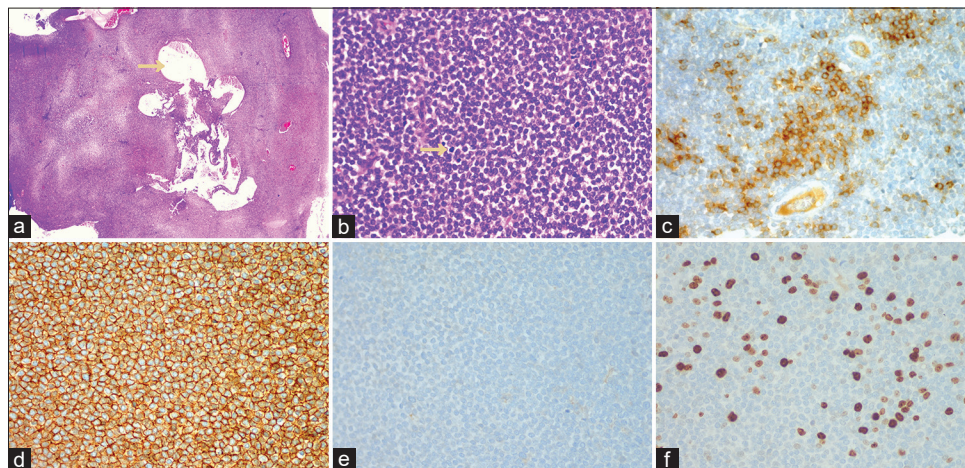
\*Corresponding author: Arunkumar Sekar, Department of Neurosurgery, All India Institute of Medical Sciences, Bhubaneswar, Odisha, India. [neurosurg\\_arun@aiimsbhubaneswar.edu.in](mailto:neurosurg_arun@aiimsbhubaneswar.edu.in)

Received: 12 September 2022 Accepted: 02 October 2022 Epub Ahead of Print: 15 December 2022 Published: 27 January 2023 DOI: 10.25259/JNRP-2022-1-33

This is an open-access article distributed under the terms of the Creative Commons Attribution-Non Commercial-Share Alike 4.0 License, which allows others to remix, transform, and build upon the work non-commercially, as long as the author is credited and the new creations are licensed under the identical terms. ©2023 Published by Scientific Scholar on behalf of Journal of Neurosciences in Rural Practice



**Figure 1:** Case 1 (a). T1-weighted image showing isointense dural based SOL in the left frontal convexity region. (b) T2-weighted image showing hyperintense SOL with areas of hypointensity in the left frontal convexity region. (c) Post-contrast image showing heterogeneous contrast enhancement in the SOL. (d) Immediate pre-operative NCCT head showing heterogeneous iso-hypodense SOL in the left frontal convexity region with subfalcine herniation. (e) Intraoperative image showing a greyish white extra-axial fleshy tumor.



**Figure 2:** Case 1 (a): Photomicrograph showing a highly cellular tumor. The tumor cells are arranged in sheet with focal cystic degenerative changes. (H&E  $\times$  40). (b) The tumor cells have high nucleocytoplasmic ratio. There is granular chromatin with scant cytoplasm. Mitotic activity was present (arrow). (H&E  $\times$  400). (c) The tumor cells are immunopositive for synaptophysin (H&E  $\times$  400). (d) The tumor cells show strong membranous immunoreactivity for CD99 (H&E  $\times$  400). (e) Staining for leukocyte common antigen (CD45) is negative. (H&E  $\times$  400). (f) MIB-1 labeling index is approximately 12%. (H&E  $\times$  400).

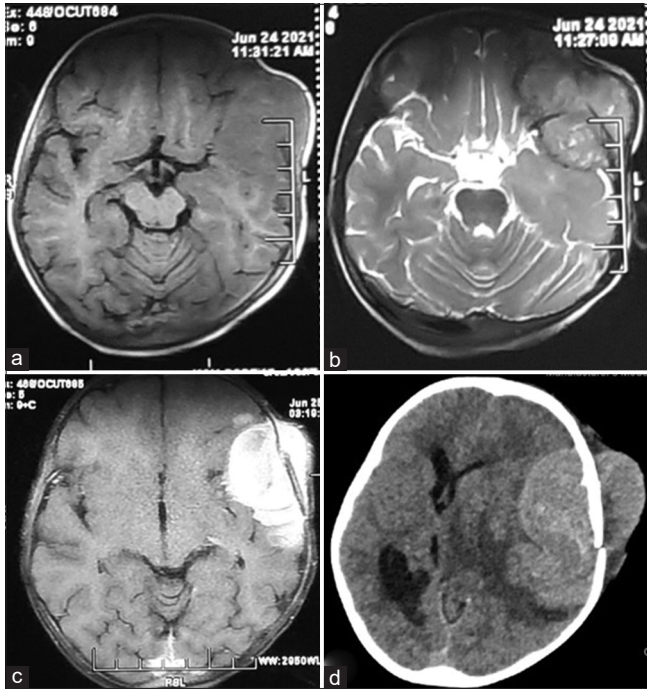
of cleavage from brain parenchyma. Histopathological examination showed ES/pPNET and immunohistochemistry was positive for CD 99, synaptophysin, CCNB3, and NSE. The baby had a stormy post-operative period developing multiorgan dysfunction and disseminated intravascular coagulation. She received continuous peritoneal dialysis

for acute renal failure and succumbed to her post-operative systemic complications.

## DISCUSSION

Intracranial ES/pPNETs are highly aggressive and rare malignancies and reported to comprise 0.03% of all





**Figure 3:** Case 2 (a) T1-weighted image showing an isointense SOL in the left fronto-temporal region. (b) T2-weighted image showing isointense extra-axial SOL in the left fronto-temporal region. (c) Post-contrast image showing intense diffuse enhancement of the SOL. (d) Immediate pre-operative NCCT head showing isodense SOL with intracranial and extracranial part with significant midline shift, perilesional edema, and subfalcine herniation.

intracranial tumors.<sup>[4]</sup> Intracranial ES/pNETs are a separate entity than the central primitive neuroectodermal tumors (cPNETs). cPNETs are tumors of embryonal origin consisting of undifferentiated or poorly differentiated neuroepithelial cells differentiating along the neuroectodermal and mesenchymal cell lines. ES/pNETs, on the other hand, are small and blue round cell tumors showing neuroectodermal differentiation arising from neural crest cells.<sup>[2]</sup> They usually occur in the young, age of onset being 15 years (median) with peak age of onset in the second decade of life (range being 5 months–57 years). The male: female ratio is 1.2, having a slight male preponderance.<sup>[5]</sup> In the report by Jiang *et al.*, the sites of intracranial ES/pNET were supratentorial hemispheric surface (60%), cerebellopontine angle (20%), cavernous sinus (10%), and posterior fossa (10%).<sup>[4]</sup> El Asri *et al.* reported similar findings with 40% of ES/pNETs being located in the cerebral convexity.<sup>[5]</sup>

Chromosomal translocation t (11,12) (q24;q12) is the most common genetic alteration in ES/pNET. EWS-FLI-1 (friend leukemia integration 1 transcription factor), a chimeric transcription factor formed as a result of this translocation, is found in 85–90% of ES/pNETs. This is due to inframe fusion of 5' end of EWSR1 gene with 3' portion of the FLI-1

gene causing downstream dysregulation of cell proliferation, differentiation, and apoptosis.<sup>[6]</sup> MIC2, a gene found in the pseudoautosomal regions of X and Y chromosomes, is expressed in very high amount in ES/pNET.<sup>[7]</sup> MIC2 expression produces CD99 which is a reliable marker for the diagnosis of ES/pNET. However, CD99 is also present in other small blue round cell tumors such as neuroblastoma, lymphoma, and rhabdomyosarcoma.<sup>[2]</sup> Both the present cases had positive immunostaining for CD99 indicating MIC2 expression. Extracranial ES/pNETs are presumed to arise from neural crest or mesenchymal stem cells and show immunopositivity for neuron specific enolase and synaptophysin.<sup>[2,8]</sup>

The second case reported had immunohistochemistry positive for CCNB3. CCNB3 immunoreactivity is a marker for the presence of BCOR-CCNB3 gene fusion.<sup>[9]</sup> BCOR and CCNB3 genes are located close together on the short arm of chromosome X.<sup>[10]</sup> BCOR-CCNB3 fusion gene is formed as a result of paracentric inversion involving the short arm of the chromosome X. The presence of BCOR-CCNB3 gene fusion was first reported in Ewing's sarcoma like tumors by Pierron *et al.*<sup>[11]</sup> BCOR-CCNB3 is usually found in EWS-FLI-1 negative tumors. To the best of our knowledge, CCNB3 immunopositive sarcoma in the intracranial location has not been previously reported in the literature.

Patients with intracranial ES/pNETs may present in acute or delayed manner. The presenting symptoms and signs depend on the location of the tumor. Supratentorial convexity tumors present with mass effect, tumors located in the skull base have cranial nerve involvement, and posterior fossa tumors may present with hydrocephalus. Symptoms due to increased intracranial pressure were also commonly seen.<sup>[5]</sup> On imaging, these tumors are T1 hypointense with variable intensity on T2-weighted images and diffuse, intense contrast-enhancement is seen on gadolinium scan.<sup>[5]</sup> Their dural based origin can result in difficulty in differentiating from meningiomas.

The management of these tumors consists of surgical excision followed by adjuvant chemotherapy. El Asri *et al.* in their review reported gross total resection in 74% of cases. They recommend aggressive total removal of the tumor whenever possible.<sup>[5]</sup> However, it may not be feasible in tumors located in difficult to access areas. Adjuvant focal radiotherapy is indicated after surgical resection. Patients in whom total resection was not possible radiotherapy lead to improved outcomes compared to patients who did not receive radiotherapy, despite both groups receiving chemotherapy.<sup>[5]</sup> El Asri *et al.* reported that 84% of patients who had adjuvant chemotherapy after surgery survived versus 53% of survival with surgery only.<sup>[5]</sup> Chemotherapy is multimodal with regimens consisting of vincristine-doxorubicin-cyclophosphamide and dactinomycin alternating with ifosfamide-etoposide. Niwa

*et al.* reported a case of ES/pPNET in an infant who developed DIC and acute renal failure in the post-operative period as the second case in our report.<sup>[12]</sup> The outcome was fatal. ES/pPNET presenting acutely and mimicking an epidural hematoma was reported by Jan *et al.*<sup>[13]</sup>

## CONCLUSION

ES/pPNET are rare and aggressive malignancies occurring in children and the young. The primary treatment is surgical. However, as reported, if the patients have poor neurological status, the prognosis is grave and even fatal.

## Declaration of patient consent

The authors certify that they have obtained all the appropriate patient consent.

## Financial support and sponsorship

Nil.

## Conflicts of interest

There are no conflicts of interest.

## REFERENCES

- Balamuth NJ, Womer RB. Ewing's sarcoma. *Lancet Oncol* 2010;11:184-92.
- Kumar V, Singh A, Sharma V, Kumar M. Primary intracranial dural-based Ewing sarcoma/peripheral primitive neuroectodermal tumor mimicking a meningioma: A rare tumor with review of literature. *Asian J Neurosurg* 2017;12:351-7.
- Huguenard AL, Li YD, Sharifai N, Perkins SM, Dahiya S, Chicoine MR. Multifocal primary central nervous system Ewing sarcoma presenting with intracranial hemorrhage and leptomeningeal dissemination: Illustrative case. *J Neurosurg Case Lessons* 2021;1:CASE2042.
- Jiang Y, Zhao L, Wang Y, Liu X, Wu X, Li Y. Primary intracranial Ewing sarcoma/peripheral primitive neuroectodermal tumor mimicking meningioma: A case report and literature review. *Front Oncol* 2020;10:528073.
- El Asri AC, Benzagmout M, Chakour K, Chaoui MF, Laaguili J, Chahdi H, *et al.* Primary intracranial pPNET/Ewing sarcoma: Diagnosis, management, and prognostic factors dilemma—a systematic review of the literature. *World Neurosurg* 2018;115:346-56.
- Desmaze C, Brizard F, Turc-Carel C, Melot T, Delattre O, Thomas G, *et al.* Multiple chromosomal mechanisms generate an EWS/FLI1 or an EWS/ERG fusion gene in Ewing tumors. *Cancer Genet Cytogenet* 1997;97:12-9.
- Ambros IM, Ambros PF, Strehl S, Kovar H, Gadner H, Salzer-Kuntschik M. MIC<sub>2</sub> is a specific marker for Ewing's sarcoma and peripheral primitive neuroectodermal tumors. Evidence for a common histogenesis of Ewing's sarcoma and peripheral primitive neuroectodermal tumors from MIC<sub>2</sub> expression and specific chromosome aberration. *Cancer* 1991;67:1886-93.
- Yim J, Lee WS, Kim SK, Kang HJ, Bae J, Park SH. Intracranial Ewing sarcoma with whole genome study. *Childs Nerv Syst* 2019;35:547-52.
- Machado I, Navarro S, Llombart-Bosch A. Ewing sarcoma and the new emerging Ewing-like sarcomas: (CIC and BCOR-rearranged-sarcomas). A systematic review. *Histol Histopathol* 2016;31:1169-81.
- Kao YC, Owosho AA, Sung YS, Zhang L, Fujisawa Y, Lee JC, *et al.* BCOR-CCNB3-fusion positive sarcomas: A clinicopathologic and molecular analysis of 36 cases with comparison to morphologic spectrum and clinical behavior of other round cell sarcomas. *Am J Surg Pathol* 2018;42:604-15.
- Pierron G, Tirode F, Lucchesi C, Reynaud S, Ballet S, Cohen-Gogo S, *et al.* A new subtype of bone sarcoma defined by BCOR-CCNB3 gene fusion. *Nat Genet* 2012;44:461-6.
- Niwa J, Shimoyama N, Takahashi Y. Primitive neuroectodermal tumor involving the frontal skull base in an infant. *Childs Nerv Syst* 2001;17:570-4.
- Jan K, Khan EK, Khan I. An unusual biconvex epidural lesion: Acutely presenting extraosseous intracranial Ewing's sarcoma. *Chin Neurosurg J* 2018;4:31.

**How to cite this article:** Datta D, Sekar A, Parameshwar VG, Purkait S, Bansal S. Intracranial peripheral primitive neuroectodermal tumor presenting as neurosurgical emergency: A report of two cases. *J Neurosci Rural Pract* 2023;14:119-22.