

Evaluation of spinous process wiring techniques for accidental canal penetration

Augustine A Adeolu^{1,2}, Abiodun L Azeez²

¹Department of Surgery, University of Ibadan, ²Department of Neurological Surgery, University College Hospital, Ibadan, Nigeria

ABSTRACT

Background and Objective: Accidental canal penetration with attendant complications constitutes one of the reasons for abandoning the use of wires for posterior spinal fusion techniques. However, there is dearth of information on this risk when the wire is introduced through the base of spinous process as against sublaminar passage. This study was designed to evaluate hardware-related postoperative complications, especially canal penetration, in our patients who had spinous process wiring in two types of posterior wiring techniques. **Materials and Methods:** Patients who had either of two spinous process wiring techniques formed the population for the study. The clinical records were reviewed and the following data were extracted: Age, sex, diagnosis, operation (fusion type), preoperative neurological status, postoperative neurologic deterioration, other postoperative complication and radiologic evidence of canal encroachment. **Results:** One hundred and seventy four spinous processes were instrumented in 42 patients. The age of the patients ranged from 11 to 78 years while male to female ratio was 2.5:1. Majority of the spinal wiring were for trauma (29 patients; 69.0) while the remaining were tumor (6; 14.3%), degenerative diseases (4; 9.5%) and infections (3; 7.1%). The Rogers technique was performed in 16 (38.1%) patients while 26 (61.9%) underwent Adeolu *et al.* technique. One patient (2.3%) had neurologic deterioration while 5 patients (11.1%) had varying type of complications from wound infection to fracture of spinous processes. There was no patient with radiological or clinical evidence of canal compromise. **Conclusion:** Spinous process wiring techniques for posterior spinal stabilization appears to be safe as demonstrated in this study.

Key words: Canal penetration, spinous process, wiring

Introduction

Wiring has been largely abandoned as a technique of posterior spinal stabilization in view of its attendant complications during passage and, subsequently, postoperative. These complications are worse with sublaminar wiring.^[1-5] However, there is dearth of information on these complications in spinous process wiring. Wire, especially monofilament, can accidentally injure the neural tissue during passage. This can occur both in sublaminar or spinous process wiring procedures. It is not common in the latter but could occur when the spinolaminar junction is breached. Furthermore, wire

can fatigue and fracture after surgery with concomitant neurological deficit. The deficit could be from direct injury from the wires or indirectly from hematoma following vascular injury. In addition, the introduction of newer techniques of fusion, like the use of pedicle screws and rods, has discouraged the use of this technique.

In spite of these disadvantages, the use of wire still has roles to play in contemporary practice; wire, whether mono-or multifilament, is cheap, easy to pass and without the need for intraoperative image intensifier. These attributes make it a suitable option when other techniques are not within reach of many patients as in several developing countries. We commonly used two types of spinous process wiring techniques in our service. These are Rogers spinous wiring and a more recently described technique by Adeolu *et al.*^[6,7] The latter share similarities with Drumond's and Bohlman's techniques with the use of vertical strut.^[8,9] However, it uses a metal vertical strut as against the use of bone slab in Bohlman's technique and it does not use buttons as in Drumond's procedure. The method of holding the vertical strut also differs from

Access this article online

Quick Response Code:



Website:
www.ruralneuropractice.com

DOI:
10.4103/0976-3147.112748

Address for correspondence:

Dr. Augustine A Adeolu, Department of Surgery, College of Medicine, University of Ibadan, P.O. Box 40476, Dugbe, Ibadan, Nigeria.
E-mail: adeoluaa@yahoo.com

other previous techniques. This study was designed to evaluate hardware-related postoperative complications, especially accidental canal penetration, in the patients who underwent the two techniques in our center.

Materials and Methods

The postoperative X-rays of patients who had spinous process wiring for spinal stabilization in our unit were reviewed. Spinous process wiring was performed either as part of Rogers wiring technique or part of stabilization techniques described by Adeolu *et al.*^[6,7] The clinical records were also reviewed and the following data were extracted: Age, sex, pathology, operation (fusion type), postoperative neurologic deterioration, complications and radiologic evidence of canal encroachment. Primary outcome measures were radiological and/or clinical evidence of canal penetration. The former was determined by the presence of the wire anterior to the spinolaminar line on lateral postoperative X-ray radiograph of the patient. New neurological deficits or presence of neurological deterioration postoperatively compared to preoperative status, which cannot otherwise be accounted for, was used as clinical evidence of canal penetration. Other postoperative complications like wound infection, wire fatigue and fracture were used as secondary outcome measures.

Results

Forty two patients with 174 instrumented spinous processes were reviewed. The age of the patients ranges from 11 years to 78 years with a male to female ratio of 2.5:1.

Majority of the spinal wiring were for trauma (29 patients; 69.0%) while 6 patients had tumor (14.3%), 4 patients had degenerative diseases (9.5%) and infection was in 3 patients (7.1%).

The Rogers wiring technique was performed in 16 patients (38.1%) and Adeolu *et al.* technique was performed in 26 patients (61.9%).

One patient (2.3%) had neurologic deterioration while 5 patients (11.9%) had varying type of complications from wound infection to fracture of spinous processes as shown in Table 1 below. There was no radiological evidence of canal compromise in any of the patients.

Figure 1 depicts plain X-ray of a patient who had interspinous wire (Rogers technique^[6]) after an anterior corpectomy with no evidence of canal penetration.

Figure 2 depicts X-ray of a patient who had thoracic laminectomy for an extradural spinal lesion followed by spinal stabilization with vertical strut and wire (Adeolu *et al.*^[7] technique).

Discussion

This study evaluated the use of two types of posterior spinal wiring techniques in various pathologies including trauma, neoplasms, infection and degenerative spinal diseases. The risk of canal compromise and as such,

Table 1: Complications from the procedure

Complication type	Number of patients
Wound infection	2
Rod migration	1
Fracture of spinous process	1
Postoperative neurological deterioration	1

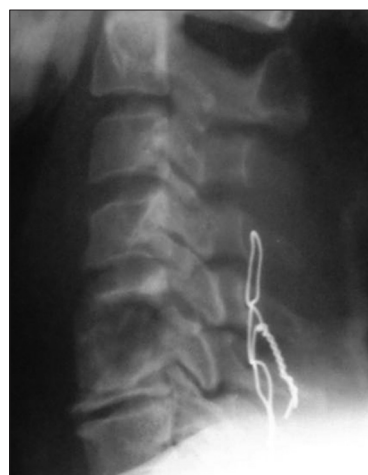

Figure 1: Cervical spine X-ray [lateral view] of a patient who had interspinous wire (Rogers technique^[6]) after an anterior corpectomy with no evidence of canal penetration

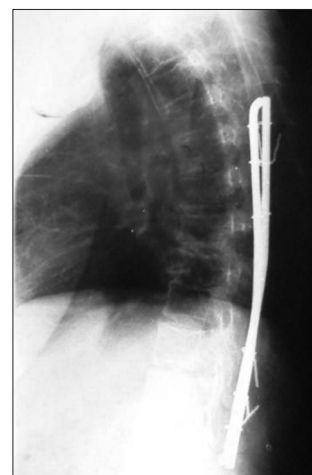


Figure 2: Thoracic spine X-ray [lateral view] of a patient who had thoracic laminectomy for an extradural spinal lesion followed by spinal stabilization with vertical strut and wire (Adeolu *et al.* technique^[7])

neuronal injuries is obviously worse with sublaminar wiring technique.^[1] However, this complication could also occur in spinous process wiring techniques.^[1] We did not identify any canal penetration in our patients. The reason for this may be multifactorial.

The technique of passing the wire through the base of the spinous process is very important. The hole for the wire in the spinous process should just be superficial to the spinolaminar junction.^[7] The direction of the wire tip through the hole should be perpendicular to the spinous process. Efforts should be made not to direct the wire tip anteriorly. This is to prevent inadvertent penetration of the spinal canal anteriorly.

Furthermore, the method of radiological evaluation used in the study has some limitation. We used plain X-ray in all the patients using the relationship of the wire to the spinolaminar line. This may not be accurate because the line may be difficult to identify with certainty especially in thoracolumbar region; the use of spinal CT scan would have been more accurate to detect this. Cost and availability of the machine were two important factors that prevented us from doing this in the patients. However, the absence of clinical evidence of canal penetration in any of our patients demonstrates the validity of the results obtained in the study in spite of the aforementioned limitations. The only patient with immediate postoperative neurological deterioration had re-exploration for suspected hematoma. However, no compressive hematoma was discovered and the implants were free from the neural tissues.

The findings in the study demonstrate the rarity of canal penetration in the two types of spinous process wiring techniques evaluated. The study suggests that if careful attention is placed to the technique of passing the wire

through the appropriate points on the spinous process, canal penetration will be prevented. The findings are especially important in developing countries where cost and availability of more sophisticated spinal hardware may pose significant challenges; wires are cheap and their passages do not require intraoperative image intensifier. The long-term complications of wire like fatigue and fractures as well as its ability to sustain the stability of the spine for prolonged period were not assessed in the study. This will form the basis for further study in the subject matter in future.

References

1. Lundy DW, Murray HH. Neurological deterioration after posterior wiring of the cervical spine. *J Bone Joint Surg Br* 1997;79:948-51.
2. Cervellati S, Bettini N, Bianco T, Parisini P. Neurological complications in segmental spinal instrumentation: Analysis of 750 patients. *Eur Spine J* 1996;5:161-6.
3. Geremia GK, Kim KS, Cerullo L, Calenoff L. Complications of sublaminar wiring. *Surg Neurol* 1985;23:629-35.
4. Goll SR, Balderston RA, Stambough JL, Booth RE Jr, Cohn JC, Pickens GT. Depth of intraspinal wire penetration during passage of sublaminar wires. *Spine (Phila Pa 1976)* 1988;13:503-9.
5. Zindrick MR, Knight GW, Bunch WH, Miller MC, Butler DM, Lorenz M, *et al.* Factors influencing the penetration of wires into the neural canal during segmental wiring. *J Bone Joint Surg Am* 1989;71:742-50.
6. Rogers WA. Treatment of Fracture-dislocation of the cervical spine. *J Bone Joint Surg Am* 1942;24:245-48.
7. Adeolu AA, Komolafe EO, Kolawole OA. The technique of using rigid vertical strut and spinous process wire for posterior spinal stabilization. *J Spinal Disord Tech* 2011;24:406-8.
8. Drummond DS, Keene J, Breed A. Segmental spinal instrumentation without spinal instrumentation. *Arch Orthop Trauma Surg* 1985;105:378-84.
9. McAfee PC, Bohlman HH, Wilson WL. The triple wire fixation technique for stabilization of acute cervical fracture-dislocations: A biomechanical analysis. *Orthop Trans* 1985;9:142.

How to cite this article: Adeolu AA, Azeez AL. Evaluation of spinous process wiring techniques for accidental canal penetration. *J Neurosci Rural Pract* 2013;4:156-8.

Source of Support: Nil. **Conflict of Interest:** None declared.