

Review Article

Parvimonas micra-related spondylodiscitis: A case report and systematic literature review

Giovan Giuseppe Mazzella¹, Calogero Velluto¹, Matteo Caredda¹, Federica Messina¹, Andrea Perna², Maria Concetta Meluzio¹, Luca Proietti¹

¹Department of Aging, Orthopaedic and Rheumatological Sciences, Fondazione Policlinico Universitario Agostino Gemelli IRCCS, Rome, Italy, ²Department of Orthopedic and Traumatology, IRCCS Casa Sollievo Della Sofferenza, San Giovanni Rotondo, Italy.

ABSTRACT

The purpose of this study is to report a case of *Parvimonas micra*-related spondylodiscitis (PMSD) and conduct a systematic review of the literature to identify clinical, microbiologic, and radiographic assessment and treatment outcomes. This research was conducted according to the Preferred Reporting Items for Systematic Reviews and Meta-Analyses guidelines. A systematic review of the Literature indexed in PubMed, MEDLINE, and Scopus databases was performed from 1970 to December 2023 using search terms “vertebral,” “spinal,” “infection,” “spondylodiscitis,” “discitis,” “osteomyelitis,” “Parvimonas,” and “micra.” The systematic review identified 34 cases of PMSD in addition to the reported case after the screening of 472 titles and abstracts. Patients reported several clinical presentations, with back pain being the most common symptom. Treatment strategies included antibiotic therapy alone or in combination with surgery, resulting in favorable outcomes for the majority of patients. However, challenges such as delayed diagnosis and lack of standardized treatment protocols were observed. The *P. micra* is an emerging pathogen in spinal infections, particularly in patients with predisposing factors. This study highlights the need for heightened awareness among healthcare providers regarding the potential role of anaerobic bacteria in spondylodiscitis. Standardized diagnostic and treatment protocols are warranted to improve outcomes for patients with PMSD.

Keywords: Spondylodiscitis, Vertebral osteomyelitis, *Parvimonas micra*, Anaerobic bacteria, Spinal infections

INTRODUCTION

Pyogenic Spondylodiscitis is uncommon; however, it is associated with several pathological conditions and has a mortality of up to 20%.^[1] This condition requires long-term antibiotic therapy and, in some cases, surgical treatment.^[2-4] The pathophysiology of spondylodiscitis is linked to the introduction of pyogenic bacteria, either directly during spinal surgery or through the bloodstream, resulting in the infectious deterioration of the vertebral body and intervertebral disc.^[5] The incidence of spondylodiscitis, particularly among individuals aged 75 years and older, has considerably increased.^[6] The clinical presentation of pyogenic spondylodiscitis typically manifests as back pain or radiating discomfort, followed by fever, neurological deficits, and systemic symptoms such as weight loss and night sweats.^[7] Elevation of laboratory parameters, including inflammatory markers such as C-reactive protein, is commonly observed at presentation and tends to correlate with the response to treatment.^[8] A microbiological diagnosis of the responsible pathogen is crucial for effective

treatment and is linked to improved clinical outcomes.^[9] Despite its rarity, anaerobic spondylodiscitis, accounting for <3% of cases of pyogenic vertebral osteomyelitis, should always be considered and pursued through microbiological investigation.^[5] Spondylodiscitis is often caused by Gram-positive aerobic bacteria, such as *Staphylococcus aureus*, with a reported incidence of around 80%.^[10] Other pathogens, such as *Escherichia coli* (a Gram-negative aerobic bacteria) and *Mycobacterium tuberculosis*, are also reported in the Literature.^[11] Anaerobic bacteria are rarely responsible for spondylodiscitis, include *Parvimonas micra*, a Gram-positive anaerobic coccus (GPAC), typically found in the oral cavity, respiratory system, gastrointestinal tract, and the female genitourinary tract. Originally identified as *Peptostreptococcus micros*, the organism was reclassified as *P. micra* in 2006.^[12] It is widely recognized as a principal oral pathogen^[13,14] and has also been implicated in meningitis,^[15] cervical and cerebral abscesses,^[16,17] infectious endocarditis,^[18] and rarely spondylodiscitis.^[19] The aim of this study is to report a case of *P. micra*-related spondylodiscitis

*Corresponding author: Calogero Velluto, Department of Aging, Orthopaedic and Rheumatological Sciences, Fondazione Policlinico Universitario Agostino Gemelli IRCCS, Rome, Italy. calogerovelluto@gmail.com

Received: 25 February 2024 Accepted: 04 May 2024 Epub Ahead of Print: 21 June 2024 Published: XXXXXX DOI: 10.25259/JNRP_72_2024

This is an open-access article distributed under the terms of the Creative Commons Attribution-Non Commercial-Share Alike 4.0 License, which allows others to remix, transform, and build upon the work non-commercially, as long as the author is credited and the new creations are licensed under the identical terms. ©2024 Published by Scientific Scholar on behalf of Journal of Neurosciences in Rural Practice

(PMSD) and to conduct a systematic review of the literature to identify clinical, microbiologic, and radiographic assessments, offering insights into treatment options and clinical outcomes.

MATERIALS AND METHODS

This research was conducted according to the Preferred Reporting Items for Systematic Reviews and Meta-Analyses (PRISMA) guidelines [Figure 1].^[20]

Search strategy

A systematic review of the Literature indexed in PubMed, MEDLINE, and Scopus databases, using search terms: “vertebral,” “spinal,” “infection,” “spondylodiscitis,” “discitis,” “osteomyelitis,” “parvimonas,” “micra,” and their medical subject headings (MeSH) terms in any possible combination, using the Boolean operator “AND” and “OR,” was performed from 1970 to December 2023. The search was reiterated until December 15, 2023. The reference lists of relevant studies were screened to identify other studies of interest.

Inclusion and exclusion criteria

Included in this review are studies reporting demographic features, symptoms, diagnostic settings, treatment, possible complications, and outcomes in patients with PMSD. Only articles written in English with available abstracts were included in the study. Excluded from this review were reports of surgical technique, expert opinions, animal studies, unpublished reports, cadaver or *in vitro* investigations, book chapters, and abstracts from scientific meetings.

Data collection

Two authors (G.G.M and C.V.) independently conducted the research by title and abstract. If the articles met the inclusion criteria, the full text was obtained and subsequently reviewed. Any discordance was resolved through consensus with a third author (M.C.). The reported items/data from the included articles encompassed: the age and gender of the patients, location of the PMSD, type of surgical treatment performed, underlying conditions, presence and location of any abscesses, presence of any immunosuppressive therapy,

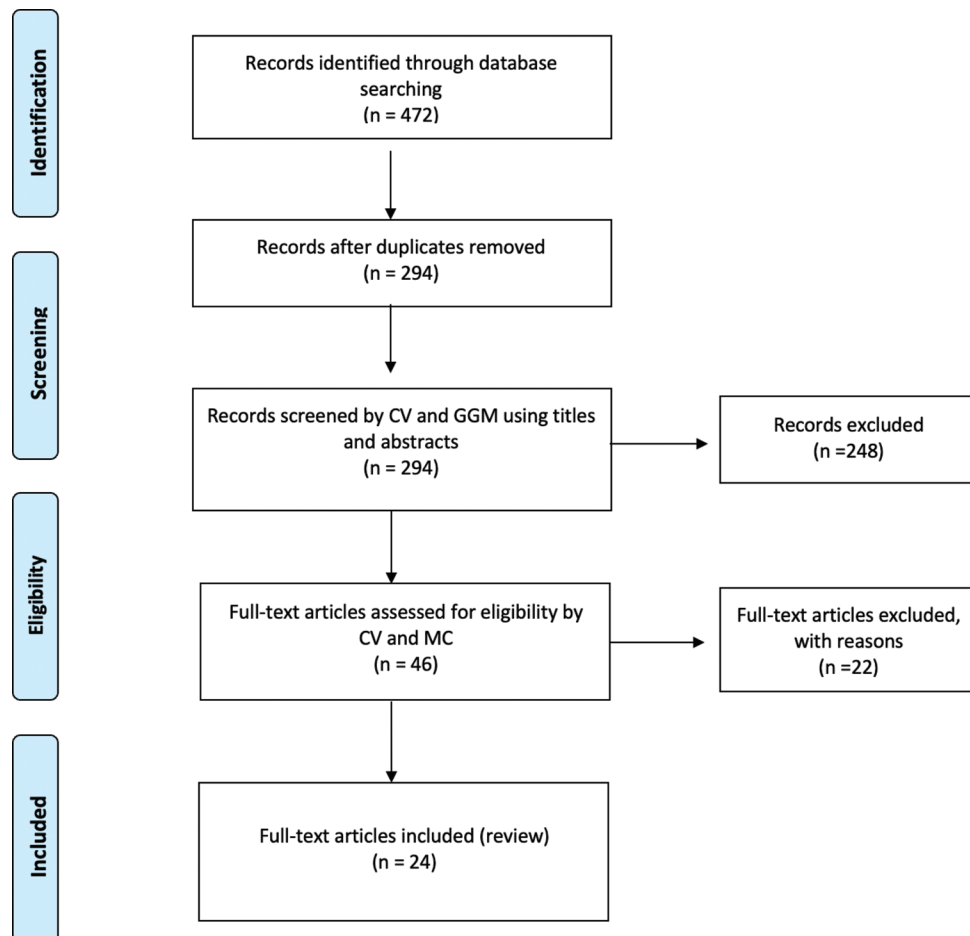


Figure 1: Preferred Reporting Items for Systematic Reviews and Meta-Analyses flow-chart. n: Number of records, GGM: Giovan Giuseppe Mazzella, CV: Calogero Velluto, MC: Matteo Caredda.

antibiotic therapy used, duration of antibiotic therapy, outcome, and complications.

Statistical analysis

Numbers software (Apple Inc., Cupertino, CA) was used to tabulate the obtained data. Categorical variables are presented as frequencies and percentages. Continuous variables are expressed as means and standard deviations.

CASE REPORT

In March 2021, a 64-year-old man with a history of Parkinson's disease and diabetes, treated with L-Dopa, dopamine agonists, and oral hypoglycemic agents, was admitted to our emergency unit due to worsening back pain, associated with urinary incontinence and a walking deficit. He had undergone total hip arthroplasty and total knee arthroplasty in 2001 following multiple fractures from a car accident. A history of chronic low back pain led to an L3-L4 discectomy at another hospital in June 2019, which initially significantly alleviated his symptoms. However, 18 months post-surgery, his low back pain gradually returned and worsened. A magnetic resonance imaging (MRI) conducted 20 days before his current presentation revealed L2-L3-L4 spondylodiscitis with hyperintensity in T2 and STIR sequences [Figure 2].

On arrival at the emergency room, a neurological examination and complete blood tests were performed. He showed no motor deficits in the upper limbs, but hypoesthesia and motor deficits were observed in the right lower limb (3/5 MRC in hip flexion, leg extension, ankle flexion, and extension). Patellar and Achilles reflexes were absent in the right limb. The visual analog scale for back pain was rated 8, and sensory disturbances in the saddle area and loss of visceral functions were noted. The latest MRI scans suggested cauda equina syndrome. Complete blood counts and blood chemistry tests were within normal limits for his age, except for elevated white blood cells at $22.96 \times 10^9/L$, neutrophils at $7.75 \times 10^9/L$, and mild thrombocytopenia ($578 \times 10^9/L$). Two sets of blood cultures were taken, indicating high inflammation rates with procalcitonin at 0.5 mg/dL and C-reactive protein at 98 mg/dL.

Due to worsening neurological symptoms, decompressive surgery was necessary. Under general anesthesia and in a prone position, a debulking of pseudomembranous tissue with a right L3 laminectomy was performed, although no purulent material was found. Large biopsy samples were taken for histological and microbiological evaluation. The intraoperative findings suggested a low likelihood of infection; hence, no empirical antibiotic therapy was

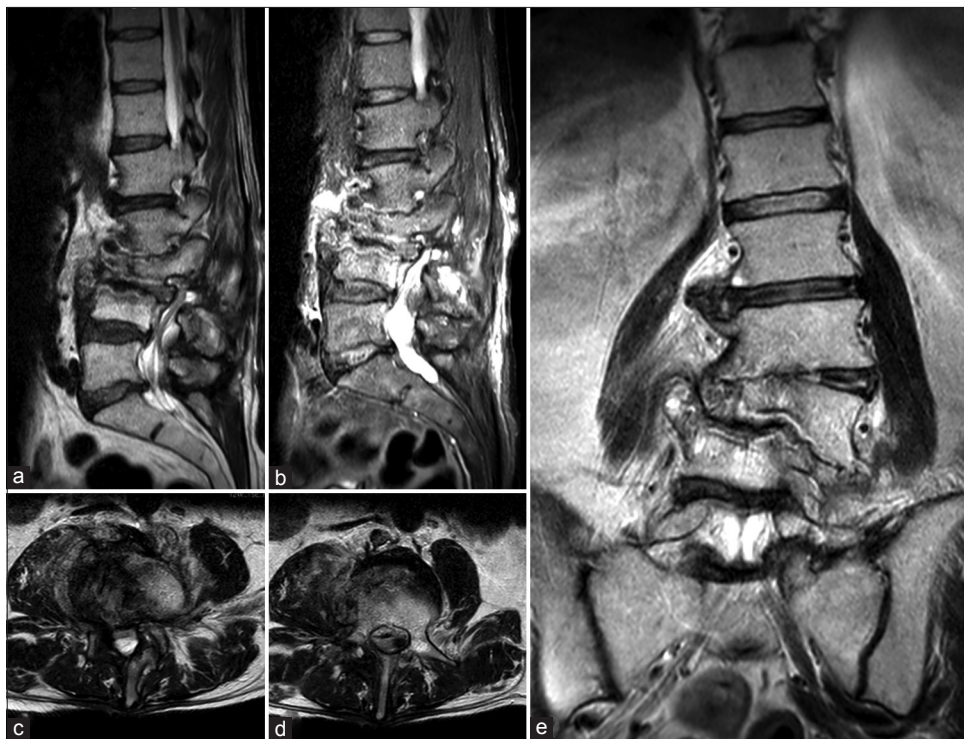

Figure 2: (a) Sagittal T2 and (b) short T1 inversion recovery (STIR)-weighted images showing hyperintensity of L2, L3, and L4 with alteration of vertebral bodies. (c and d) Axial T2-weighted images showing hyperintensity of the right iliopsoas and of the vertebral body of L4. (e) Coronal T2-weighted view showing L3 collapse with complete disruption of L2-L3 and L3-L4 discs.

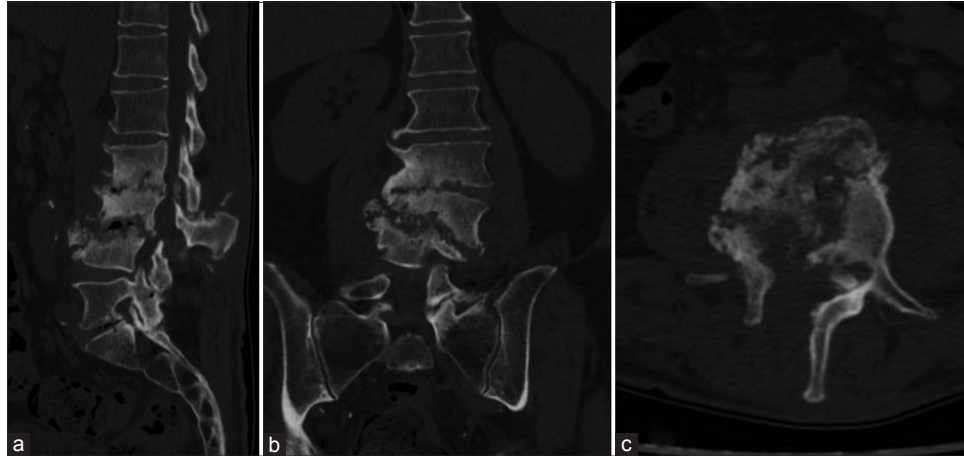


Figure 3: (a) Sagittal, (b) coronal, and (c) axial post-operative computed tomography scans of the patient affected by *Parvimonas micra*-related spondylodiscitis, showing complete structural alteration of L2, L3, and L4 and the presence of laminectomy, as shown in the (c) axial view.

initiated. The patient was discharged two days later in good clinical and neurological condition, free from back pain.

A post-operative computed tomography (CT) scan was conducted [Figure 3], and a lumbar custom-made brace was prescribed for early mobilization. Close outpatient follow-up was initiated to monitor clinical outcomes. Histological analysis confirmed chronic inflammation, and the intraoperative samples tested positive for *P. micra*. Consequently, targeted antibiotic therapy with amoxicillin/clavulanate (Augmentin 875/125 mg every 6 h) was initiated. One month post-procedure, neurological examinations showed no signs suggestive of cauda equina syndrome. The patient ceased antibiotic therapy two months later and began weaning from the brace. Conservative treatment continued for three months until a decrease in all inflammatory markers, including C-reactive protein, was observed. At the 12-month follow-up, he was in good health, without neurological signs or limitations in walking. A CT scan confirmed vertebral fusion between L2, L3, and L4 [Figure 4]. The patient's post-operative follow-up was managed by a multidisciplinary team including a spine surgeon and an infectious disease specialist. Two years post-event, the patient reported no low back pain and an Oswestry Disability Index score of 22%. All procedures performed adhered to the 1964 Helsinki Declaration. Due to the retrospective nature of the research and the use of de-identified patient data, the Institutional Review Board waived the need for ethical review and approval. Written informed consent for scientific purposes and clinical data collection was obtained in accordance with institutional protocols.

LITERATURE REVIEW

After screening 472 titles and abstracts, we identified 46 papers deemed eligible for full-text analysis. Among these, 24

studies meeting inclusion criteria were ultimately included in the review. In total, including our report, 35 patients affected by PMSD were analyzed in this systematic review.^[19,21-43]

Demographical data

The mean age of the included patients was 65.3 (8–86) years. Two (5.7%) were pediatric (<18 years old), and 22 (62.8%) were elderly (>65 years old). Among the included patients, 19 (54.3%) were male, and 16 (45.7%) were female. Demographic and clinical data are presented in Table 1.

Localization, presentation symptoms, and underlying conditions

In this literature review of PMSPD, several clinical scenarios are detailed, shedding light on the multifaceted nature of lower back pain associated with PMSD.

The PMSD involved the thoracic spine in three patients (8.6%) and the thoracolumbar spine area in seven patients (20%). The lumbar spine was involved in 20 (79.2%) patients, whereas the cervical spine was involved in two patients (5.7%, Gahier *et al.* and Medina *et al.*).^[33,35] In one patient, no abnormalities were noted in the CT scan (Shimizu *et al.*).^[23] A single level of spondylodiscitis was reported in 29 cases. On the other side, multi-level involvement was described in four patients. In 25.7% (9 patients), the infection was related to the presence of a paraspinal abscess that affected the psoas muscle. Among these, only one patient showed an intraspinal abscess (Durovic *et al.*).^[24] In one patient, there was extraspinal localization: Miyazaki *et al.* reported the clinical history of a patient, who exhibited a significant pleural effusion in his left thoracic cavity, necessitating drainage through a thoracotomy tube.^[25] Two patients experienced bloodstream infection with severe compromise of organs

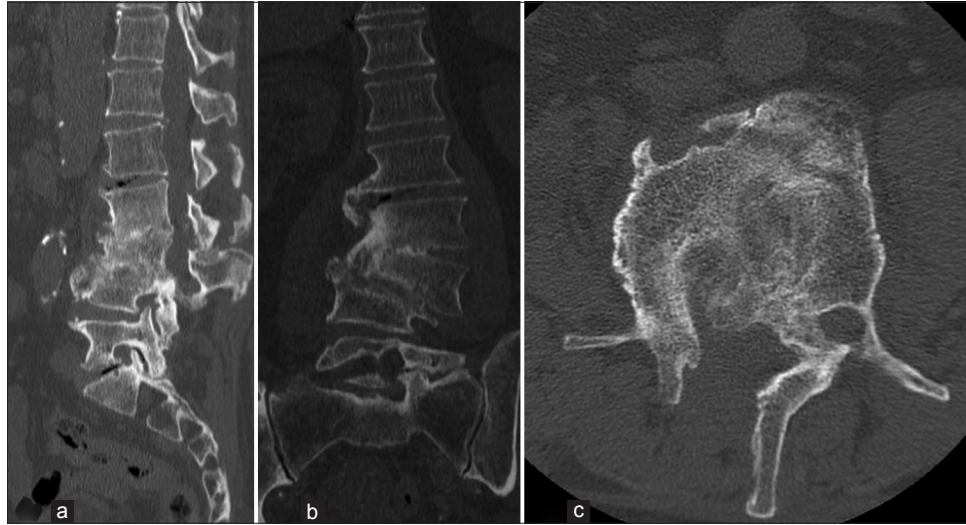


Figure 4: (a) Sagittal, (b) coronal, and (c) axial computed tomography scan images at 12 months follow-up, showing vertebral fusion of L2-L3-L4.

functionality. The most frequent presentation symptom was low back pain. Notably, the cases by Paul *et al.* (2023) and Yoo *et al.* (2019) reported acute exacerbations of lower back pain in individuals with chronic health conditions.^[22,26] The study by Shimizu *et al.* (2022) described a unique case of persistent fever and pulsated headaches in a patient with a history of dental treatment, emphasizing the potential oral origin of PMSD.^[23] Medina *et al.* reported a case of an atypical presentation of Lemierre's syndrome.^[35] Van Duijvenbode's *et al.* case (2018) reported a patient with severe leg and lumbar spine pain postoperatively: laminectomy of L3-L5 was performed 1.5 years before his visit, due to lumbar stenosis as a result of degenerative lumbar deformity.^[27] Cleaver *et al.* (2017) reported a case of PMSD related to Klippel-Trenaunay syndrome.^[29] Twelve patients (34.3%) had no comorbidities at the moment of hospitalization. No patients were immunocompromised, even though Miyazaki *et al.* reported a history of a patient with a background of prostatic cancer and diabetes mellitus (DM).^[25] These conditions might have compromised his immune system and disrupted host defenses, potentially facilitating the entry of *P. micra* into his bloodstream. The most commonly reported predisposing conditions for PMSPD were previous spine or dental surgeries, although a primary focus of infection was frequently undetermined. In this review, 17 patients (48.6%) had no recorded details regarding the portal of infection. Uemura *et al.* suggested that advanced age might constitute another significant risk factor for *P. micra*-induced spondylodiscitis.^[19]

Diagnosis

The diagnosis of PMSD varied among the included studies, with six authors, namely, Paul *et al.*, Cleaver *et al.*, Higashi

et al., Jones *et al.*, Pilmis *et al.*, George *et al.*, and Medina *et al.* relying on matrix-assisted laser desorption ionization time-of-flight mass spectrometry for a total of 8 patients (22.8%).^[22,29-32,35,36] Shimizu *et al.*, Durovic *et al.*, Gahier *et al.*, and Yoo *et al.* employed blood cultures for diagnosis, representing 11 patients (31.4%).^[23,24,26,33] Van Duijvenbode *et al.* opted for intraoperative cultures.^[27] Miyazaki *et al.*, Endo *et al.*, and Uemura *et al.* utilized 16S rRNA gene sequencing for three patients (8.6%).^[19,25,34] Notably, Uemura *et al.* additionally utilized isolation by culture (RapID-ANA) in triplicate for one patient (2.85%).^[19] However, Mizuta *et al.*, Dahya *et al.*, Gonzalez *et al.*, Fraisse *et al.*, Brook *et al.*, Leder *et al.*, Rousseau *et al.*, and Papasian *et al.* did not disclose their specific diagnostic approaches in their respective studies.^[28,37-43] This diversity underscores the need for standardized diagnostic protocols in the field of PMSD.

Treatment options

Antibiotic therapy alone was administered in 16 patients (45.7%). In 18 patients (51.4%), a combination of medical and surgical treatment was described, while one patient (2.8%) suffered a transient bacteremia resolved spontaneously. In two cases (5.7%), a CT-guided biopsy was performed, in one case a percutaneous biopsy (2.85%, Gonzalez *et al.*), in four cases (11.4%) a surgical biopsy was reported, in three cases (8.6%) abscess drainage, in four cases (11.4%) posterior decompression, and in five cases (14.3%) posterior decompression and fusion.^[38] Combination antibiotic treatment was prescribed in all cases, except one. The most commonly used antibiotic was amoxicillin/clavulanic acid (40%), followed by clindamycin (31.4%) and gentamicin (14.3%). In 31 (88.6%) cases, the duration of antibiotic therapy was reported. The mean duration was 61.2 days. Dahya *et*

Table 1: Demographic data of patients and systematic review.

Author	Year	Age, years	Sex	Initial presentation	Comorbidities	Surgical treatment	Antibiotic treatment	Primary focus of infection	Outcome
Mazzella et al. (current study)	2024	64	M	Lower back pain associated with urinary incontinence and walking deficit	Parkinson disease, diabetes, THA, TKA, L3-L4 discectomy	Debridement and L3 laminarthrectomy and decompression	Amoxicillin/clavulanate 875/125 mg cpr OS every 6 h for 2 months	Unknown	No relapse
Kalmoukos et al. ^[21]	2023	68	F	Lower back pain and lower extremities pain	Rheumatoid arthritis, Osteoporotic vertebral fractures T12-L1	None	Penicillin, clindamycin, 8 weeks	Hematogenous	No relapse
Paul et al. ^[22]	2023	70	F	Lower back pain	Chronic lymphocytic leukemia in remission, autoimmune hemolytic anemia, DM, hypertension, hypothyroidism, right THA	T9-L3 stabilization with T12 laminectomy	Vancomycin and cefepime 1 week; on 7 th day meropenem 1 g 3 times daily, based on the positive <i>Parvimonas micro</i> report	Dental caries in the left maxillary molar	No relapse
Shimizu et al. ^[23]	2022	54	M	Persistent fever and pulsated headaches	Hypertension and stroke	None	NO (transient bacteremia that resolved spontaneously)	History of dental treatment, oral contamination, a painful mouth	No relapse
Durovic et al. ^[24]	2022	82	M	Acute immobilizing pain of the lower back and in both shoulder joints	Renal failure	Acute paraplegia resulting from the abscesses, emergency decompression T12-L5 with laminectomy of L2-4	Empiric antibiotic therapy with amoxicillin/clavulanic acid	Several tooth root granulomas	Death unrelated to spondylodiscitis
	69	M		Lower back pain for 3 weeks and new hyposensitivity of the left thigh	Gout	CT-guided biopsy	14 days of IV amoxicillin/clavulanic acid; oral amoxicillin for an additional 4 weeks	A single episode of fever following a tooth extraction 10 days before the back pain began	No relapse
	72	M		Back pain for 2 weeks	Decompressive spinal surgery due to spinal stenosis in L1-L5				
	72	F		Persistent lower back pain for 6 weeks	Coronary heart disease	CT-guided biopsy; followed by an open discectomy with drainage of the abscess	Empiric antibiotic therapy with amoxicillin/clavulanic acid; after identification penicillin IV for 2 weeks, and later amoxicillin orally for an additional 4 weeks	Dental procedure	Not reported
	72	M		Lumbago for 3 months	Renal failure	Fenestration and evacuation of the abscess	5 weeks of IV treatment with amoxicillin/clavulanic acid; oral moxifloxacin for an additional 6 weeks	No primary focus of infection	Not reported
	63	F		Lower back pain for 6 weeks	DM II	Transpedicular and disc open biopsy	Penicillin and ertapenem IV for 2 weeks. Clindamycin for a further 12 weeks for treatment of chronic osteomyelitis	No primary focus of infection	No relapse
Miyazaki et al. ^[25]	2019	83	F	Lower back pain; tenderness and stabbing pain in his left thigh, accompanied by an erythematous rash	Renal failure	None	Amoxicillin/clavulanic acid intravenously for 14 days, followed by oral amoxicillin for 6 weeks	Persistent inflammation of a molar following a dental procedure	Persistent pain
Yoo et al. ^[26]	2019	77	F	Acute on chronic lower back pain, aggravated by heavy lifting	Prostatic cancer, DM, hypertension and hyperuricemia	None	2 g of meropenem and 1200 mg of clindamycin daily	Not identified	Died of multiple organ failure on the 3 rd day of his hospitalization
Van Duijvenbode et al. ^[27]	2018	78	M	Severe pain in right leg and in the lumbar spine	Cerebrovascular accident, hypertension, hyperlipidemia and osteoporosis	Not required surgical intervention	IV ceftriaxone 2g once daily and IV metronidazole, dual cover with IV ceftriaxone and oral metronidazole (8-week course of ceftriaxone and 5-week course of metronidazole)	Not identified	Relapse-free 4 months after discharge
Mizuta et al.	2018	86	F	Lower back pain	Bilateral THA, revision of the left THA, left TKA, hypertension, ulcerative colitis	Decompression of L2 and L3 and a posterior spondylosis T12-L5	Vancomycin and ciprofloxacin, after cultures results 12 g daily penicillin IV for 2 weeks, oral clindamycin 600 mg 3 times daily for 4 weeks	Laminectomy of L3-L5 performed 1.5 years before, collapse of the vertebral bodies of L2 and L3, compression of right nerve root and spinal stenosis at L3	Occasional back pain at 1 year after surgery
Cleaver et al. ^[28]	2017	45	F	8 week history of lumbar back pain	Not reported	None	Metronidazole 7 weeks	Unknown	Not reported
Higashi et al. ^[30]	2017	67	M	Progressive lower back pain for 2 months	Klippel-Trenaunay syndrome, copper intrauterine device <i>in situ</i> since 2009	CT-guided vertebral biopsy; 6 days post-biopsy, percutaneous posterior spinal stabilization T10-L3	Empirically, postoperatively intravenous teicoplanin, piperacillin-tazobactam and amikacin; IV ertapenem, 1 g once daily, and oral clindamycin, 450mg 4 times daily, for a total of 6 weeks	Some years previously, dental cavity filling and some subsequent dental hygienist procedures, but good oral health	At 6 week follow-up, no spinal pain, with a tender but non-erythematous operative site
Jones et al. ^[31]	2015	72	M	4 weeks of back pain	DM II	Blood culture and transcutaneous vertebral biopsy; L4-S1 decompression and instrumented spinal fusion	IV ampicillin/subactam; on day 19 of admission, ampicillin (8 g/day) until day 72 of admission	Periodontitis	Recovered
George et al. ^[32]	2015	49	M	3 months of back pain, without fever or constitutional symptoms	None	Core biopsy	6 weeks of IV piperacillin+tazobactam, then 2 weeks of oral amoxicillin+clavulanate	Uncomplicated tooth extraction 2 months before follow-up	Relapse-free after 12-month follow-up
Gahier et al. ^[30]	2015	59	F	3 week history of progressive low back pain	Chronic osteoarthritis involving both hips and spine	Core biopsy of the T5 vertebral lesion and aspirate of the right paravertebral abscess	IV piperacillin+tazobactam for 4 weeks	Cervical spinal corticosteroid injections many years prior	Relapse-free after 5-month follow-up
	82	F		Spondylololthesis with L3-L4 decompression and instrumented spinal fusion 6 months earlier	None	Debridement of soft tissue due to epidural abscess at L2-L3 and removal of the spinal hardware	IV ceftriaxone and oral metronidazole for 6 weeks	Dental work with tooth extraction	Normal inflammatory markers at 3 months follow-up
	60	F		None	None	None (6 blood cultures)	IV gentamicin, metronidazole and amoxicillin later replaced by amoxicillin alone for 14 weeks	Dental caries with an apical granuloma	Full recovery
	60	F		None	None	None (blood culture)	IV ceftriaxone and gentamicin replaced by amoxicillin for 6 weeks	Dental apical granuloma	Positive clinical outcome
	60	F		None	None	None (blood culture)	IV ceftriaxone and gentamicin, later replaced by amoxicillin for 12 weeks	Portal of entry not identified	Positive clinical and biological outcome
Endo et al. ^[34]	2015	55	F	Persistent lower back pain (2 months) despite a treatment with NSAIDs and morphine	None	Laminoplasty and debridement of the epidural abscess	High-dose IV subactam/ampicillin (6 g daily) for 6 weeks, followed by oral metronidazole (1500 mg daily) for 10 weeks in total	Dental treatment before the onset of low back pain	Complete recovery
Medina et al. ^[35]	2015	23	F	3-week history of fever associated with headache and dorsal paravertebral myalgia	None	None	Amoxicillin/clavulanic acid; rifampicin/clindamycin for 8 weeks	Hematogenous	Successful
Pilmis et al. ^[36]	2015	83	M	Chronic lower back pain without fever	Left hip/right knee joint surgery and an ischaemic heart disease	Laminectomy L4-L5, four samples removed from the L4 and L5 vertebral bodies	IV amoxicillin and gentamicin for fifteen days followed by oral clindamycin and rifampicin for a total duration of 3 months	No tooth infection or any portal of entry including gastrointestinal	No relapse was noted in a 6-months follow-up
Dahya et al. ^[37]	2015	62	M	3-day history of fever, chills and intractable lumbar back pain	Hepatitis C, status after liver transplantation, Spinal stenosis	None	Vancomycin/Ceftriaxone	Endocarditis/Hematogenous	Successful
Gonzalez et al. ^[38]	2014	62	M	Lumbar back pain and weakness in lower left limb of 6 months duration	Degenerative joints disease	Percutaneous biopsy T7-T8	Clindamycin for 4 months	Unknown	Successful
Uemura et al. ^[39]	2014	83	M	Lower back pain of 6-week duration, tenderness over L3	Hypertension	Surgical biopsy of the vertebral bones	3 g ampicillin-subactam every 6 h for 8 weeks, 625 mg oral amoxicillin-clavulanate every 8h for 4 weeks	Periodontitis	No relapse after 10 months
Fraisse et al. ^[39]	2009	75	M	Worsening malaise, anorexia of 1-month duration	Right hemiparesis	None, blood culture	Empiric doripenem IV for 12 days, IV ampicillin 3 g for 4 weeks, oral amoxicillin 500 mg every 6h for 8 weeks	Periodontitis	No relapse
Brook ^[40]	2001	10	M	6 weeks of low back pain, fever, abdominal pain	DM, hypercholesterolemia	None	Amoxicillin/Clavulanic acid+gentamicin, amoxicillin/clindamycin for 12 weeks	Hematogenous	Successful
Leider and Barlan ^[41]	2000	70	M	Low back pain, fever	None	None	Oral amoxicillin	Unknown	Successful
Rousseau and Harlé ^[42]	1998	82	F	Lower back pain	None	None	Clindamycin	Unknown	Successful
Papasian et al. ^[43]	1986	70	M	Not reported	Ulcerative colitis, osteoarthritis, benign prostatic hypertrophy	None	Amoxicillin/Metronidazole	Paraspinal abscess	Successful
				Not reported	None	None	Amoxicillin	Unknown	Successful
				Not reported	Cataract operations, TURP, right inguinal herniorrhaphy	None	Naefillin-clindamycin, 6 weeks	Unknown	Successful

THA: Total hip arthroplasty, TKA: Total knee arthroplasty, DM: Diabetes mellitus, TURP: Transurethral resection of the prostate, IV: Intravenous, NSAIDs: Non-steroidal anti-inflammatory drugs.

al., Brook and Rousseau *et al.* had not reported the duration of therapy.^[37,40,42] At the time, the case report was published, antibiotic therapy was still ongoing in no case.

Outcomes

The clinical outcomes were reported in 33 cases (94.3%). Twenty-eight (80%) had a complete recovery: They were relapse free at the last follow-up visit. Three patients (8.6%) complained of persistent lumbar back pain but an improvement in the radiological picture was observed. Two patients (5.7%) died during follow-up from causes unrelated to spondylodiscitis. A complication was reported in one patient: A *Clostridium difficile* infection occurred three weeks after completion of antimicrobial therapy.^[26]

DISCUSSION

The *P. micra*, a GPAC, typically inhabits the normal oropharyngeal flora. Formerly classified as *Peptostreptococcus micros*, this bacterium also resides as a commensal in the gastrointestinal and urogenital tracts, though it infrequently leads to serious infections.^[12] Infections involving *P. micra* typically arise within polymicrobial infections, originating from established microbial colonies, and its dissemination through the bloodstream can result in metastatic infections. The literature most commonly documents cases of endodontic infections and oropharyngeal abscesses, with pleural empyema and intra-abdominal abscesses being less common.^[13] Papiasian *et al.* reported the first case of vertebral osteomyelitis secondary to *P. micra* in 1986.^[43] Since then, only a few works on this topic can be found in the literature, indicating that PMSDs are a clinical entity still being defined.^[27] Most cases of spondylodiscitis result from the blood-borne spread of bacteria originating from remote infection sites, predominantly involving *S. aureus*, and to a smaller degree, Enterobacteriaceae and Streptococci.^[24] Recognizing the causative microorganism of spinal infection is essential for timely and effective management but can be challenging in some cases. Due to the poor sensitivity of blood cultures, specific growth needs and slow propagation of the bacterium, along with negative spinal biopsies, identifying the responsible pathogen often requires several attempts, which can delay treatment.^[24] Typically, detecting anaerobic bacteria in spinal biopsies is uncommon, with *Cutibacterium acnes* and *Bacteroides fragilis* being the species most frequently found.^[44] The elderly population is at the greatest risk of developing spinal infections, and the lumbar area is the most affected. Additional significant risk factors include DM, intravenous drug use, and previous spinal surgeries^[11] and recent dental procedures. In a recent systematic review of the literature, Van Duijvenbode *et al.* suspected an odontogenic focus in 50% of cases;^[27] moreover, Durovic *et al.*, in a case series of six patients with PMSD,

suspected a dental focus as the source of infection in four out of six patients, with a short rest between dental infection and symptoms of spondylodiscitis, indicating a clear correlation between recent dental procedures and the development of PMSD.^[24] The clinical presentation of patients with PMSD is generally a history of worsening back pain, associated or not with mild systemic inflammatory signs. In cases where symptoms are more severe, it is common to administer empiric broad-spectrum antibiotics before pinpointing the infection's source and identifying the responsible pathogen. According to the 2015 guidelines from the Infectious Diseases Society of America (IDSA), a 6-week course of parenteral antimicrobial treatment is advised for the majority of patients suffering from bacterial vertebral osteomyelitis.^[45] In cases of acute neurological compromise or pyogenic abscesses requiring evacuation and drainage, surgical treatment must be associated in addition to targeted antibiotic therapy.^[26] MRI of the spine is considered the decisive method for assessing patients exhibiting signs or symptoms that may indicate spondylodiscitis. If results are uncertain, CT-guided biopsies, or open biopsies when necessary, are regarded as the definitive diagnostic tools. The guidelines from the IDSA state that a positive blood culture for *S. aureus* is adequate to confirm the infection source when spondylodiscitis is identified through MRI.^[45] We performed a systematic review of the literature to define a correct diagnostic approach to PMSD that allows for timely treatment, whether pharmacological or surgical, which would improve the prognosis of these patients. The systematic review revealed the increasing incidence of spondylodiscitis, particularly among individuals aged 75 years and older, and emphasizes the importance of timely diagnosis and effective treatment to improve clinical outcomes. The clinical presentation of pyogenic spondylodiscitis typically manifests as back pain or radiating discomfort, along with fever, neurological deficits, and systemic symptoms. Laboratory parameters such as inflammatory markers play a crucial role in diagnosis and treatment response monitoring. Furthermore, while Gram-positive aerobic bacteria, particularly *S. aureus*, are commonly implicated in spondylodiscitis, our study highlights the rare occurrence of anaerobic spondylodiscitis, with *P. micra* being identified as one such pathogen. Radiological outcomes in our case report play a pivotal role in the comprehensive evaluation of PMSD, providing crucial insights into disease progression and treatment response. As shown in Figure 2, there was a complete disruption of bone associated with degenerative changes, such as vertebral endplate erosion and disc space narrowing. These findings offer valuable diagnostic clues, while assessments of sagittal and coronal balance highlight mechanical instability and potential neurological compromise. In our case, the patient reported symptoms including radiculopathy and severe back pain, which prompted emergency decompression

surgery. Furthermore, in accordance with infectious disease recommendations, antibiotic therapy was initiated along with immobilization using a brace. These radiological and clinical parameters contribute to a holistic approach to managing this challenging condition, guiding therapeutic decisions, and optimizing patient outcomes.

In addressing the distinctive characteristics and clinical considerations of PMSD, our analysis reveals several points of interest that warrant further elucidation in the results section of the manuscript. First, the impact of *P. micra* on spondylodiscitis appears to diverge from more common pathogens due to its anaerobic nature, potentially contributing to a delayed diagnosis and subsequent treatment initiation, as the organism requires specific conditions for growth and identification in cultures.^[19,24,43] Radiologically, PMSD does not present with uniquely distinguishing features when compared to other causes of spondylodiscitis; however, the propensity for abscess formation, particularly paraspinal, may be more pronounced given the anaerobic and polymicrobial tendencies of the infection.^[19,26,27] The treatment duration for PMSD, while not inherently longer, must be prudently tailored to each case, often employing a combination of surgical intervention and targeted antibiotic therapy, with the duration guided by the patient's clinical response and the resolution of symptoms and laboratory markers of infection.^[45] *P. micra*'s role in spondylodiscitis is further underscored by its association with dental procedures, a potential primary source for infection spread through hematogenous routes.^[19,24] In addition, risk factors such as prior spinal surgery, immunocompromised states, and the presence of other comorbid conditions play a significant role in the susceptibility to PMSD, delineating the need for heightened vigilance and targeted diagnostic strategies in at-risk patient populations.^[11,19,37] Collectively, these insights into the pathogenicity, diagnosis, and management of PMSD contribute to a better understanding of this unique clinical entity, emphasizing the need for prompt and appropriate diagnostic and therapeutic measures to mitigate its impact on patient outcomes.

Thus, a comprehensive evaluation encompassing both radiological outcomes and reported symptoms is essential in the management of PMSD, facilitating timely diagnosis, treatment planning, and monitoring of disease progression. Future research efforts should focus on elucidating the optimal diagnostic modalities, treatment strategies, and outcomes associated with PMSD. Collaborative endeavors are essential to accumulate larger datasets that can inform evidence-based guidelines for the management of this rare but potentially debilitating condition. Ultimately, our study contributes valuable insights to the existing literature and underscores the need for continued vigilance and research in the field of infectious spondylodiscitis, with specific attention to the role of *P. micra* as a causative pathogen.

CONCLUSION

P. micra is a potential causative agent in spinal infections, particularly in patients with underlying risk factors such as dental or gastrointestinal pathologies. The systematic literature review revealed a limited but growing body of evidence implicating *P. micra* in spondylodiscitis, emphasizing the need for heightened awareness among spine surgeons. Early detection is crucial for implementing timely and effective therapeutic interventions. In addition, the review sheds light on the diverse treatment approaches reported in the literature, emphasizing the absence of standardized guidelines for managing PMSD.

Acknowledgments

Giovan Giuseppe Mazzella and Calogero Velluto contributed equally.

Authors' contributions

Conceptualization, GGM, CV, LP. Methodology, GGM, LP. Data curation, GGM, CV. Formal analysis, MCM, CV. Investigation, GGM, CV, FM, MC. Validation, CV, FM, MC, LP. Writing – original draft preparation, GGM, CV. Writing – review and editing GGM, CV. Visualization, FM, MC, LP. Supervision, LP. All authors have read and agreed to the published version of the manuscript.

Ethical approval

The Institutional Review Board has waived the ethical approval for this study.

Declaration of patient consent

The authors certify that they have obtained all appropriate patient consent.

Financial support and sponsorship

Nil.

Conflicts of interest

There are no conflicts of interest.

Use of artificial intelligence (AI)-assisted technology for manuscript preparation

The authors confirm that there was no use of artificial intelligence (AI)-assisted technology for assisting in the writing or editing of the manuscript and no images were manipulated using AI.

REFERENCES

1. Rutgers JP, Kempen DH, van Dijk M, Oner FC. Outcome of conservative and surgical treatment of pyogenic

- spondylodiscitis: A systematic literature review. *Eur Spine J* 2016;25:983-99.
2. Taylor DG, Buchholz AL, Sure DR. Presentation and outcomes after medical and surgical treatment versus medical treatment alone of spontaneous infectious spondylodiscitis: A systematic literature review and meta-analysis. *Glob Spine J* 2018;8:49S-58.
 3. Li YD, Wong CB, Tsai TT. Appropriate duration of post-surgical intravenous antibiotic therapy for pyogenic spondylodiscitis. *BMC Infect Dis* 2018;18:468.
 4. Perna A, Ricciardi L, Sturiale CL, Fantoni M, Tamburrelli FC, Bonfiglio N, et al. Skipped vertebral spontaneous spondylodiscitis caused by *Granulicatella adiacens*: Case report and a systematic literature review. *J Clin Orthop Trauma* 2020;11:937-41.
 5. Chen CT, Wu MH, Huang TY, Li YY, Huang TJ, Lee CY, et al. Anaerobic spondylodiscitis: A retrospective analysis. *BMC Musculoskelet Disord* 2022;23:788.
 6. Thavarajasingam SG, Subbiah Ponniah H, Philipps R, Neuhoff J, Kramer A, Demetriades AK, et al. Increasing incidence of spondylodiscitis in England: An analysis of the national health service (NHS) hospital episode statistics from 2012 to 2021. *Brain Spine* 2023;3:101733.
 7. Smimmo A, Perna A, Fantoni M, De Marco D, Velluto C, Proietti L, et al. Non tuberculous mycobacteria related spondylodiscitis: A case report and systematic literature review. *Infez Med* 2020;28:425-35.
 8. Santagada DA, Perna A, Tullo G, Proietti L, Vitiello R, Ferraro S, et al. Could serum procalcitonin play a role in an emergency setting for patients with pyogenic spondylodiscitis? *Eur Rev Med Pharmacol Sci* 2022;26(1 Suppl):66-77.
 9. Chong BS, Brereton CJ, Gordon A, Davis JS. Epidemiology, microbiological diagnosis, and clinical outcomes in pyogenic vertebral osteomyelitis: A 10-year retrospective cohort study. *Open Forum Infect Dis* 2018;5:ofy037.
 10. Herren C, Jung N, Pishnamaz M, Breuninger M, Siewe J, Sobottke R. Spondylodiscitis: Diagnosis and treatment options. *Dtsch Arztebl Int* 2017;114:875-82.
 11. Duarte RM, Vaccaro AR. Spinal infection: State of the art and management algorithm. *Eur Spine J* 2013;22:2787-99.
 12. Tindall BJ, Euzéby JP. Proposal of *Parvimonas* gen. nov. and *Quatrionicoccus* gen. Nov. as replacements for the illegitimate, prokaryotic, generic names *Micromonas* Murdoch and Shah 2000 and *Quadracoccus* Maszenan et al. 2002, respectively. *Int J Syst Evol Microbiol* 2006;56:2711-3.
 13. Murdoch DA. Gram-positive anaerobic cocci. *Clin Microbiol Rev* 1998;11:81-120.
 14. Nickles K, Scharf S, Röhlke L, Mayer I, Mayer M, Dickholz P. Detection of subgingival periodontal pathogens--comparison of two sampling strategies. *Clin Oral Investig* 2016;20:571-9.
 15. Ko JH, Baek JY, Kang CI, Lee WJ, Lee JY, Cho SY, et al. Bacteremic meningitis caused by *Parvimonas micra* in an immunocompetent host. *Anaerobe* 2015;34:161-3.
 16. Frat JB, Godet C, Grollier G, Blanc JL, Robert R. Cervical spinal epidural abscess and meningitis due to *Prevotella oris* and *Peptostreptococcus micros* after retropharyngeal surgery. *Intensive Care Med* 2004;30:1695.
 17. Shtaya A, Schuster H, Riley P, Harris K, Hettige S. Oesophageal pleural fistula presenting with *Parvimonas micra* infection causing cervical and brain abscesses. *Anaerobe* 2017;47:233-7.
 18. Wenisch C, Wiesinger E, Werkgartner T, Makristathis A, Graninger W. Treatment of *Peptostreptococcus micros* endocarditis with teicoplanin. *Clin Infect Dis* 1995;21:446-7.
 19. Uemura H, Hayakawa K, Shimada K, Tojo M, Nagamatsu M, Miyoshi-Akiyama T, et al. *Parvimonas micra* as a causative organism of spondylodiscitis: A report of two cases and a literature review. *Int J Infect Dis* 2014;23:53-5.
 20. Moher D, Shamseer L, Clarke M, Ghersi D, Liberati A, Petticrew M, et al. Preferred reporting items for systematic review and meta-analysis protocols (PRISMA-P) 2015 statement. *Syst Rev* 2015;4:1.
 21. Kalmoukos P, Kouroupis D, Sapouridis G, Simoulidou E, Varouksi A, Zarras C, et al. Anaerobic spondylodiscitis caused by *Parvimonas micra* in a rheumatoid arthritis patient: Case report and review of the literature. *Mediterr J Rheumatol* 2023;34:525-30.
 22. Paul V, Kling K, Santoiemma PP. A rare anaerobic cause of vertebral osteomyelitis and psoas abscess: A case study. *IDCases* 2023;34:e01900.
 23. Shimizu K, Horinishi Y, Sano C, Ohta R. Infection route of *Parvimonas micra*: A case report and systematic review. *Healthcare (Basel)* 2022;10:1727.
 24. Durovic A, Eberhard N, Schären S, Widmer AF. *Parvimonas micra* as a rare cause of spondylodiscitis - case series from a single centre. *Swiss Med Wkly* 2020;150:w20272.
 25. Miyazaki M, Asaka T, Takemoto M, Nakano T. Severe sepsis caused by *Parvimonas micra* identified using 16S ribosomal RNA gene sequencing following patient death. *IDCases* 2019;19:e00687.
 26. Yoo LJ, Zulkifli MD, O'Connor M, Waldron R. *Parvimonas micra* spondylodiscitis with psoas abscess. *BMJ Case Rep* 2019;12:e232040.
 27. Van Duijvenbode DC, Kuiper JW, Holeywijn RM, Stadhouders A. *Parvimonas micra* spondylodiscitis: A case report and systematic review of the literature. *J Orthop Case Rep* 2018;8:67-71.
 28. Mizuta K, Sonohata M, Nozaki O, Kobatake T, Nakayama D, Morimoto T, et al. Metronidazole-induced encephalopathy in a patient with pyogenic spondylitis: A case report. *BMC Musculoskelet Disord* 2018;19:336.
 29. Cleaver LM, Palanivel S, Mack D, Warren S. A case of polymicrobial anaerobic spondylodiscitis due to *Parvimonas micra* and *Fusobacterium nucleatum*. *JMM Case Rep* 2017;4:e005092.
 30. Higashi Y, Nakamura S, Niimi H, Ueno T, Matsumoto K, Kawago K, et al. Spondylodiscitis due to *Parvimonas micra* diagnosed by the melting temperature mapping method: A case report. *BMC Infect Dis* 2017;17:584.
 31. Jones SL, Riordan JW, Glasgow AL, Botes J, Boutlis CS. Two cases of spondylodiscitis caused by *Parvimonas micra*. *Intern Med J* 2015;45:1090-1.
 32. George IA, Pande A, Parsaei S. Delayed infection with *Parvimonas micra* following spinal instrumentation. *Anaerobe* 2015;35(Pt B):102-4.
 33. Gahier M, Cozic C, Bourdon S, Guimard T, Cormier G. Spinal infections caused by *Parvimonas micra*. *Med Mal Infect*

- 2015;45:397-8.
34. Endo S, Nemoto T, Yano H, Kakuta R, Kanamori H, Inomata S, et al. First confirmed case of spondylodiscitis with epidural abscess caused by *Parvimonas micra*. J Infect Chemother 2015;21:828-30.
 35. Medina F, Tatay M, Smati M, Aoun O, Tankovic J, Bouchaud O, et al. Lemierre's syndrome: An unusual presentation. Med Mal Infect 2015;45:328-30.
 36. Pilmis B, Israel J, Le Monnier A, Mizrahi A. Spondylodiscitis due to anaerobic bacteria about a case of *Parvimonas micra* infection. Anaerobe 2015;34:156-7.
 37. Dahya V, Chalasani P, Ramgopal M. *Peptostreptococcus* endocarditis presenting as lumbar discitis in an immunocompromised patient. Am J Med Sci 2015;349:187-8.
 38. González MG, Montes JR, Rosado DG, Reyes SB. Multifocal hematogenous vertebral osteomyelitis due to *Parvimonas micra* and a subsequent pleural effusion in a diabetic patient. Reumatol Clin 2014;10:191-2.
 39. Fraisse T, Lavigne JP, Lechiche C, Leroux JL, Sotto A. Spondylodiscitis due to *Peptostreptococcus* spp: A case report. Joint Bone Spine 2009;76:104-5.
 40. Brook I. Two cases of diskitis attributable to anaerobic bacteria in children. Pediatrics 2001;107:26.
 41. Leder KS, Barlam TF. A case of paraspinal abscess and diskitis due to *Peptostreptococcus micros*. Clin Infect Dis 2000;30:622-3.
 42. Rousseau MC, Harlé JR. Spondylitis caused by *Peptostreptococcus*. Clin Rheumatol 1998;17:538-9.
 43. Papasian CJ, McGregor DH, Hodges GR, Kennedy J. Peptostreptococcal vertebral osteomyelitis. J Clin Microbiol 1986;24:633-5.
 44. Gouliouris T, Aliyu SH, Brown NM. Spondylodiscitis: Update on diagnosis and management. J Antimicrob Chemother 2010;65 (suppl 3):iii11-24.
 45. Berbari EF, Kanj SS, Kowalski TJ, Darouiche RO, Widmer AF, Schmitt SK, et al. 2015 Infectious Diseases Society of America (IDSA) clinical practice guidelines for the diagnosis and treatment of native vertebral osteomyelitis in adults. Clin Infect Dis 2015;61:e26-46.

How to cite this article: Mazzella G, Velluto C, Caredda M, Messina F, Perna A, Meluzio M, et al. *Parvimonas micra*-related spondylodiscitis: A case report and systematic literature review. J Neurosci Rural Pract. doi: 10.25259/JNRP_72_2024