

# Tuberculous brain abscesses: Case series and review of literature

Sarala Menon, Renu Bharadwaj, AS Chowdhary, DV Kaundinya, DA Palande<sup>1</sup>

Departments of Microbiology and <sup>1</sup>Neurosurgery, Grant Medical College and Sir J.J. Hospital, Mumbai, India

## ABSTRACT

**Introduction:** Tuberculous brain abscess (TBA) is a rare but serious condition. It resembles a pyogenic brain abscess clinically and radiologically and poses a problem in diagnosis and treatment. A final diagnosis is established by smear or culture demonstration of acid fast bacilli (AFB) within the abscess. Here, we report four such cases in our five-year study on brain abscesses, along with the different diagnostic modalities used. **Materials and Methods:** A total of 75 brain abscess pus specimens were collected during neurosurgery, either by burr hole or by craniotomy. These specimens were further subjected to Gram stain, Ziehl-Neelsen (ZN) stain, and conventional microbiological culture. Only those cases which showed presence of AFB on ZN stain along with the growth of *Mycobacterium tuberculosis* were considered as TBAs. Such TBA cases were further presented along with their *In vitro* Proton Magnetic Resonance (MR) Spectroscopic findings. **Results:** Of these four patients, three were males. Though this condition is more commonly seen in immunocompromised patients, three of the patients in this study were immunocompetent. All the four pus specimens showed presence of AFB in the ZN stain. Three of them grew *M. tuberculosis* as sole isolate. The fourth case was of concomitant tuberculous and pyogenic brain abscess. *In vitro* Proton MR spectroscopy of the pus specimens showed absence of multiple amino acids at 0.9 ppm, which was found to be hallmark of TBA. One patient died of four. **Conclusions:** TBA always poses a diagnostic dilemma. ZN stain and conventional microbiological culture for *Mycobacteria* always help to solve this dilemma. *In vitro* Proton MR Spectroscopy also seems to have the diagnostic utility.

**Key words:** Brain abscess, pyogenic, tuberculous MR Spectra

## Introduction

Tuberculous brain abscess (TBA) is a rarely reported form of central nervous system (CNS) *tuberculosis*.<sup>[1]</sup> TBA is a focal collection of pus containing abundant acid fast bacilli (AFB) surrounded by a dense capsule consisting of vascular granulation tissue.<sup>[2]</sup> TBA always poses a diagnostic dilemma as they are difficult to differentiate from pyogenic brain abscesses, tuberculous meningitis, and tuberculoma on the basis of clinical, laboratory, and roentgenographic information.<sup>[1]</sup> Whitener,<sup>[1]</sup> in his excellent review, had laid down the diagnostic criteria for

TBA. The present study reports four cases of TBA along with comparative analysis of other TBA cases from the available literature.

## Materials and Methods

During the 5-year study on brain abscesses, pus specimen was collected during neurosurgery either by burr hole or by craniotomy. This was then sent to Department of Microbiology for the subsequent workup after obtaining proper consent. This study was performed after obtaining necessary ethical clearance from the institutional ethical committee.

Gram and Ziehl-Neelsen (ZN) stains were performed immediately. Aerobic, anaerobic, and fungal cultures were put up using conventional methods.<sup>[3]</sup> Pus specimens were also inoculated on Lowenstein Jensen's medium and incubated at 37°C for 6 to 8 weeks. Colonies obtained were confirmed to be acid fast by ZN and then were identified by conventional methods such as rate

### Access this article online

#### Quick Response Code:



**Website:**  
www.ruralneuropractice.com

**DOI:**  
10.4103/0976-3147.83581

#### Address for correspondence:

Dr. Sarala Menon, Department of Microbiology, Grant Medical College and Sir J.J. Hospital, Mumbai – 400 008, India.  
E-mail: drsaralamenon@gmail.com

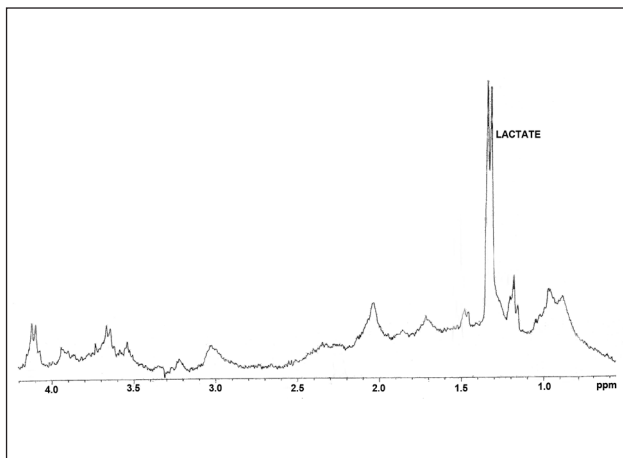
of growth, pigment production, niacin accumulation, nitrate reduction test, and sensitivity to paranitrobenzoic acid (500µg/ml).<sup>[3]</sup>

In three TBA cases, 100 µl of pus sample was loaded in 5 mm NMR tube and deuterium oxide (D<sub>2</sub>O) (Armar Chemicals, Switzerland) was added to make approximate volume of 0.6 ml, and then subjected to *In vitro* Proton MR Spectroscopy (<sup>1</sup>H MRS) using Mercury plus Varian 300 MHz (7.05 T) nuclear MR spectrometer. After the NMR analysis (256 scans), the different peaks obtained were noted. Referencing was done with the water peak at 4.8 ppm. The interpretation of peaks was done according to the available literature.<sup>[4,5]</sup> The spectra of pus which yielded *Mycobacterium tuberculosis* were further compared with spectra of pus that yielded pyogenic organisms.

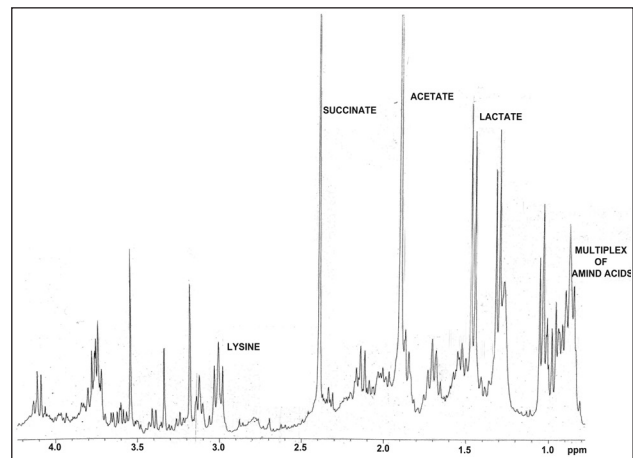
## Results

Of 75 pus specimens, ZN stain revealed presence of AFB

in four (5.3%). Three pus specimens grew *M. tuberculosis* as the sole pathogen causing the brain abscess. In one case, along with *M. tuberculosis*, pus specimen showed growth of *Enterococcus avium* and *Proteus vulgaris*. Table 1 shows all the details of the patients encountered in the present study. Of these four cases, three were immunocompetent, while one patient was infected with Human Immunodeficiency Virus(HIV). Two of the pus specimens which yielded pure growth of *M. tuberculosis* subjected to *in vitro* <sup>1</sup>H MRS showed complete absence of multiplet of amino acids-lipids at 0.9 ppm and lactate + lipid at 1.3 ppm [Figure 1a]. Pus from pyogenic brain abscesses (anaerobic) showed presence of multiplet of amino acids-lipids at 0.9 ppm along with presence of lactate + lipid at 1.3 ppm, acetate at 1.92 ppm, and succinate at 2.4 ppm [Figure 1b]. However, the pus specimen which yielded *M. tuberculosis* along with *E. avium* + *P. vulgaris* showed spectra similar to pyogenic brain abscess.



**Figure 1a:** *In vitro* 1H MRS of the pus specimen which grew *Mycobacterium tuberculosis* on culture



**Figure 1b:** *In vitro* 1H MRS of the pus specimen which grew anaerobe on culture

**Table 1: Details of the patients from the present study**

Age/Sex	Presenting signs and symptoms	Immune status	Lobe involved	Extra CNS TB	ZN stain	Culture results	<i>In vitro</i> MR spectroscopy
47/M	Fever, loss of consciousness, It hemiparesis, History of fall, convulsions	Immunocompetant	Frontal	Nil	AFB seen	<i>M tuberculosis</i>	Absence of amino acids at 0.9 ppm, lactate –lipd at 1.3 ppm
23 years/M	Decease in vision, headache, fever, giddiness	Immunocompetant	Multiple	Pulmonary	AFB seen	<i>M tuberculosis</i>	Not done as specimen was inadequate
25 years/M	Headache, convulsions	Immunocompromised : HIV infected	Parieto-occipital	Pulmonary	AFB seen	<i>M tuberculosis</i>	Absence of amino acids at 0.9 ppm, lactate –lipd at 1.3 ppm
15 years/F	Headache, vomiting, fever, CSOM	Immunocompetant	Temporal	Nil	AFB seen	<i>M tuberculosis, Enterococcus avium and Proteus vulgaris</i>	Multiplet of amino acids at 0.9 ppm, lactate –lipid at 1.3 ppm, acetate at 1.92 ppm

## Discussion

*M. tuberculosis* is a rare cause of brain abscess; however, this organism should be considered in patients with disseminated *tuberculosis* or in individuals from areas where *tuberculosis* is endemic.<sup>[2]</sup> The present study noticed four (5.4%) TBA cases in five-year study on brain abscesses. In all these four cases, there was an evidence of pus within the brain and bacteriological proof of AFB in the pus by microscopy as well as by culture. In 1978, Whitner<sup>[1]</sup> reported a case of TBA and reviewed 57 similar cases in the world literature. He found that only 16 of the 57 cases could be considered as verified TBAs in terms of the following three criteria: 1. Macroscopic evidence from surgical or autopsy material of true abscess formation within the brain substance, characterized by cavity formation with central pus; 2. Sufficient histological description to assure that the inflammatory reaction in the abscess wall was composed predominantly of vascular granulation tissue containing acute and chronic inflammatory cells particularly polymorphonuclear leukocytes; and 3. Proof of *tuberculosis* origin by either a positive culture of the pus for *M. tuberculosis* or demonstration of acid-fast organisms in the pus or abscess wall. After Whitner<sup>[1]</sup> reviewed the world literature, isolated cases of TBAs have been reported.<sup>[6-17]</sup> In most of these cases, proof of *tuberculosis* origin was by either a positive culture of the pus for *M. tuberculosis* or demonstration of acid-fast organisms in the pus, except in the study by Kaushik et al.,<sup>[15]</sup> the diagnosis was confirmed by Polymerase chain reaction (PCR) for *M. tuberculosis* MPB64. Thus, newer techniques like PCR may provide useful tool for diagnosis of *tuberculosis* from paucibacillary specimens like pus in which conventional methods may show low sensitivity. Even in the present study, a new technique, *In vitro* <sup>1</sup>HMRS, was evaluated for the diagnosis of TBA. Absence of multiplet of amino acids-lipids at 0.9 ppm seems to be a hallmark of TBAs. Similar findings have been reported in the literature.<sup>[18,19]</sup> An attempt was made to compare these spectra with the pus specimen, which showed pure growth of anaerobe (pyogenic brain abscess). Pus specimens which showed the presence of anaerobes on culture revealed the presence of multiplet at 0.9 ppm, along with lactate-lipid at 1.3 ppm, acetate at 1.92 ppm, and succinate at 2.4 ppm [Figure 1a and b]. The case of concomitant tuberculous and pyogenic brain abscess showed spectra similar to pyogenic brain abscess. However, succinate (marker for anaerobes) peak was absent suggesting that the pus specimen may have facultative anaerobes. As there are no major peaks in TBA except that of lactate-lipid, the total spectra were masked by the pyogenic abscess spectra. However, the

Gram stain, ZN stain, and gold standard conventional culture gave the complete etiological diagnosis.

Whitner's<sup>[1]</sup> review of 16 cases also revealed the following common features in TBA: 1. Frequent occurrence of TBA in the third and fourth decade of life; 2. A 35% incidence of multiple brain abscesses; 3. Predominant supratentorial location of the abscess in the frontal lobe; 4. Evidence of extra CNS *tuberculosis* in 85% cases; and 5. Occurrence of TBA despite antituberculous treatment and presentation with rapidly progressive neurological deficit.

Contrary to Whitner's<sup>[1]</sup> observations, one of our patients was a 15-year-old girl. Table 2 clearly shows that TBA can occur at any age. Of four cases in the present study, one (25%) of the patients presented with multiple brain abscesses involving temporal, parietal, and occipital lobe. Remaining three cases had a solitary abscess involving frontal, temporal, and parietal lobe. Multiple TBA is rare, with only a few reports appearing in the literature.<sup>[17,20]</sup> Table 2 also shows that TBA can occur in any part of brain involving the ventricles.<sup>[10]</sup>

In the present study, the coexistence of pulmonary *tuberculosis* was seen in two patients. CNS *tuberculosis* occurs secondary to hematogenous spread of *M. tuberculosis* from pulmonary Koch's.<sup>[15]</sup>

Among the laboratory diagnostic modalities used, ZN stain and culture were found to detect the presence of AFB in all the four cases. Table 1 shows that three of the pus specimens grew *M. tuberculosis* as sole isolate. The fourth case was of concomitant tuberculous and pyogenic brain abscess. A second concomitant pathogen with TBA is rare.<sup>[21]</sup> There are very few reports of concomitant tuberculous and pyogenic brain abscess that appeared in the literature, namely dual infection due to *Streptococci*,<sup>[12]</sup> *Toxoplasma*,<sup>[21]</sup> and *Echinococcus*.<sup>[22]</sup>

TBAs are an unusual clinical presentation of central nervous system tuberculosis occurring extremely infrequently in developed countries, and almost always in immunocompromised patients. TBA is an uncommon clinical entity, even in countries where *tuberculosis* is endemic.<sup>[23]</sup> It occurs in only 4 to 8% of patients with CNS TB who do not have HIV infection<sup>[1]</sup> but in 20% of patients who do have HIV infection.<sup>[24,25]</sup> We encountered one such case which yielded a pure growth of *M. tuberculosis*. Fischl et al.<sup>[21]</sup> described a case of TBA and toxoplasma encephalitis in a Haitian woman with AIDS. Farrar et al. reported TBA in a 43-year-old man with a history of intravenous drug use. Vidal et al.<sup>[13]</sup> (2003) reported a case of TBA in a patient with AIDS. They also reviewed the

**Table 2: Details of tuberculous brain abscess patients from the available literature**

Study	Age/ Sex	Presenting symptoms	Immune status	Lobe involved	Extra CNS TB	ZN stain results	Culture results	Other tests
Whitener, 1978	25/M	Sore throat, throat pain, fever, swelling of the left side of neck, and jaw	Immuno- competant	Frontal	Nil	AFB seen	<i>M. tuberculosis</i> -----	
Mohanty and Rao, 1978	20/F	History of progressive impairment of memory, and insomnia, intermittent headaches, vomiting, right-sided focal convulsions, several attacks of brief unconsciousness.	Immuno- competant	Frontal	Nil	No AFB seen	<i>M. tuberculosis</i> -----	
Chandramuki <i>et al</i> , 1981	37/M	Headache, giddiness, vomiting, blurring of vision, fever, bilateral papilloedema	Immuno- competant	Cerebellar	Pulmonary	AFB seen	-----	-----
	13/F	Bifrontal headache, convulsions, neck stiffness, bilateral papilloedema, facial palsy	Immuno- competant	Fronto-temporal	Abdominal	AFB seen	<i>M. tuberculosis</i> -----	
Inbasekaran and Natarajan, 1991	4/F	Headache, vomiting, unsteady walking	Immuno- competant	Cerebellar	Pulmonary	Bacteriological examination showed <i>M tuberculosis</i>	-----	-----
Farrar <i>et al</i> , 1997	43/F	Intravenous drug user, Focal seizure, involuntary movement of leg,	HIV infected	Fronto- parietal	Nil	AFB seen	<i>M. tuberculosis</i> -----	
Vajramani <i>et al</i> ,1999	26/F	Fever, neck pain, double vision, neck stiffness	Immuno- competant	Intraven-tricular	Nil	AFB seen	-----	-----
Babu and Shavinder, 2001	40/M	Fever, headache, vomiting		CT showed hypodense lesions surrounded by enhancing ring	History of TB in one patient	AFB seen	-----	-----
	35/F	Fever, headache, vomiting				AFB seen	-----	-----
Siddiqui <i>et al</i> , 2001	55/M	Headache, vomiting, altered conscious-ness, neck rigidity, left sided hemiparesis	Diabetic	Parietal	Nil	AFB seen	<i>M. tuberculosis</i> , Streptococci	-----
	42/F	Occipital headache, fever, left sided weakness, bilateral papilloedema, It sided motor deficit	Immuno- competant	Occipital	Nil	No AFB seen	<i>M. tuberculosis</i> , Streptococci	-----
Vidal, <i>et al</i> , 2003	34/F	Headache, seizures	HIV infected,	Frontal	Nil	AFB seen	-----	-----
Chatto- padhyay and Kundu, 2006	15/M	Fever, headache, vomiting, convulsions, double vision, left sided hemiparesis	Immuno- competant	Frontal	Nil	AFB seen	-----	-----
Kaushik <i>et al</i> , 2007	26/M	Fever, headache, altered sensorium, neck stiffness, papilloedema	HIV infected	Parietal	Pulmonary	No AFB seen	Negaive for pyogenic organisms, <i>M tuberculosis</i> and fungi	PCR + MPB64
Somale <i>et al</i> , 2009	11/F	Headache, blurring vision, vomitingleft eye prominent, seizure in the past, unilateral proptosis	Immuno- competant	Parieto- temporo- occipital	Tubercular lymph- adenitis: cervical and abdominal	AFB seen	No growth	-----

Table 2: (Contd..)

Study	Age/ Sex	Presenting symptoms	Immune status	Lobe involved	Extra CNS TB	ZN stain results	Culture results	Other tests
Narang <i>et al</i> , 2010	2/F	Fever, paroxysmal cough, decreased movement of Right side of body, drowsiness, decreased acceptance of food, papilloedema	Immuno- competant	Multiple	Bilateral military mottling in chest X-ray	No AFB seen	<i>M. tuberculosis</i>	PCR + for <i>M. tuber- culosis</i>

literature from 1981 to 2002 and found eight cases of TBAs in HIV infected patients. Kaushik *et al.*<sup>[15]</sup> also reported TBA in a 26-year-old male who was HIV seropositive.

Of these four patients, from the present study, patient no. 1 died who also had an altered level of consciousness at the time of admission. He also gave history of fall but no history of extra CNS *tuberculosis*. Rest three patients were put on anti-Koch's treatment and being followed up regularly.

## Acknowledgements

Authors appreciate the help of Mr.Moombasawallah, Ms.Nutan and Ms Sonali, RSIC, IIT, Powai, Mumbai for obtaining the NMR spectra.

## References

- Whitener DR. Tuberculous brain abscess. *Arch Neurol* 1978;35:148-55.
- Mathiesen GE, Johnson JP. Brain abscess. *Clin Infect Dis* 1997;25:763-79.
- Baron EJ, Peterson LR, Finegold SM. Bailey and Scott's Diagnostic Microbiology. 9th ed. St Louis: Mosby; 1994.
- Lai PH, Li KT, Hsu SS, Hsiao, CC, Yip CW, Ding S, *et al*. Pyogenic brain abscess: Findings from in vivo 1.5-T and 11.7T in vitro proton MR spectroscopy. *AJNR Am J Neuroradiol* 2005;26:279-88.
- Maheshwari S, Mukherji S. Proton MR Spectroscopy: Clinical applications. *The Journal of Imaging Technology Management* 2002. Available from: [http://www.imagingeconomics.com/issues/articles/2002-08\\_04.asp](http://www.imagingeconomics.com/issues/articles/2002-08_04.asp) [Last accessed on 2007 June 10].
- Mohanty S, Rao CJ. Tuberculous abscess of the brain. *Postgrad Med J* 1978;54:678-9.
- Chandramuki A, Rao TV, Rao AN. Tuberculous brain abscess Report of two cases. *Neurol India* 1981;29:38-42.
- Inbasekaran V, Natarajan M. Tuberculous brain abscess. *J Indian Med Assoc* 1991;89:207, 209.
- Farrar DJ, Timothy P, Flanigan, Gordon NM, Gold RL, Rich JD. Tuberculous brain abscess in a patient with HIV infection: Case report and review. *Am J Med* 1997;102:297-301.
- Vajramani GV, Devi BI, Hegde T, Santosh V, Khanna N, Vasudev MK. Intraventricular tuberculous abscess: A case report. *Neurol India* 1999;47:327-9.
- Babu ML, Shavinder. Tubercular brain abscess. *JK-Pract* 2002;9:262-3.
- Siddiqui AA, Sarwari AR, Chishti KN. Concomitant tuberculous and pyogenic tuberculous brain abscess. *Int J Tuberc Lung Dis* 2001; 5:100-1.
- Vidal JE, Cimerman S, Silva PR, Sztajnbok J, Coelho JF, Lins DL. Tuberculous brain abscess in a patient with AIDS: Case report and literature review. *Rev Inst Med Trop Sao Paulo* 2003;45:111-4.
- Chattopadhyay P, Kundu AK. *Tuberculosis* of brain abscess. A diagnostic and therapeutic challenge. *J Assoc Physicians India* 2006;54:829-30.
- Kaushik K, Karade S, Kumar S, Kapila K. Tuberculous brain abscess in a patient with HIV infection. *Indian J Tuberc* 2007;54:196-8.
- Somale A, Malik S, Tyagi D, Joshi S, Srinath BK, Kadakia P. Tubercular abscess presenting as unilateral proptosis –A diagnostic challenge. *Bombay Hosp J* 2009; Special issue 41-4.
- Narang M, Gomber S, Upreti L, Dua S. Multiple intracranial tubercular abscesses in a child. *Kathmandu Univ Med J* 2010;8:244-6.
- Gupta RK, Vatsal DK, Husain N, Chawla S, Prasad KN, Roy R, *et al*. Differentiation of tuberculous from pyogenic brain abscesses with in vivo Proton MR Spectroscopy and magnetization transfer MR imaging. *Am J Neuroradiol* 2001;22:1503-9.
- Husain N, Sharma S, Verma R, Shukla N, Gupta RK, Prasad KN, *et al*. Multimodal Diagnostic Approach to Brain Abscess. *Internet J Trop Med* 2007;3(2). Available from: <http://www.ispub.com/ostia/index.php?xmlFilePath=journals/ijtm/vol3n2/brain.xml> [Last assessed on 2007 Oct 13].
- Sharma V, Newton C. Multiple tuberculous brain abscesses. *Indian J Tuberc* 1992;39:185-6.
- Fischl MA, Pitchenik AE, Spira TJ. Tuberculous brain abscess and toxoplasma encephalitis in a patient with the Acquired Immuno Deficiency Syndrome. *JAMA* 1985;253:3428-30.
- Obrader S, Urquiza P. Two cases of cerebral abscess of unusual nature, tuberculous brain abscess and suppurative hydatid cyst. *J Neurosurg* 1980;15:572-5.
- Bottiau E, Noe A, Florence E, Colebunders R. Multiple tuberculous brain abscesses in an HIV-infected patient successfully treated with HAART and antituberculous treatment. *Infection* 2003;31:118-20.
- Sanchez-Portocarrero J, Perez-Cecilia E, Romero-Vivas J. Infection of the central nervous system by Mycobacterium tuberculosis in patients infected with human immunodeficiency virus (the new neurotuberculosis). *Infection* 1999;27:313-7.
- Cárdenas G, Soto-Hernández JL, Orozco RV, Silva EG, Revuelta R, Amador JL. Tuberculous Brain Abscesses in Immunocompetent Patients: Management and Outcome. *Neurosurgery* 2010;67:1081-7.

**How to cite this article:** Menon S, Bharadwaj R, Chowdhary AS, Kaundinya DV, Palande DA. Tuberculous brain abscesses: Case series and review of literature. *J Neurosci Rural Pract* 2011;2:153-7.

**Source of Support:** Nil. **Conflict of Interest:** None declared.