

## Fulminant post-craniotomy wound infection and meningitis with pneumocephalus caused by *Acinetobacter baumannii*: An unusual presentation

Sir,

*Acinetobacter baumannii* (AB) is being increasingly recognized as an important cause of multi-drug-resistant nosocomial infections.<sup>[1]</sup> In neurosurgical literature it has been associated with secondary intracranial infections (post-traumatic/post-surgical meningitis and abscess formation).<sup>[2-5]</sup> Recently, AB has been implicated in necrotizing soft-tissue infections.<sup>[6-8]</sup> A similar type of fulminant wound infection after craniotomy has not been described. We report an unusual case where we had a combination of such wound infection with meningitis and pneumocephalus.

A 45-year-old male presented with a one-month history of progressively increasing left-sided focal motor seizures and features of raised intracranial pressure. He had undergone surgery and radiotherapy for a right frontotemporal astrocytoma (Grade 2) three years back. The magnetic resonance imaging (MRI) brain revealed a right frontal enhancing mass [Figure 1]. He reported high-grade intermittent fever with chills since a week and at the time of admission had anemia, thrombocytopenia and pre-renal azotemia. The peripheral smear was positive for schizonts and merozoites of *Plasmodium vivax*. After appropriate antimalarial and supportive

medical management he was operated eight days after his admission. On the sixth postoperative day he developed craniotomy flap swelling which in an hour's time had markedly progressed to involve the entire scalp. He also became confused and incoherent. A computed tomography (CT) scan revealed significant scalp edema with air pockets in the subcutaneous and subgaleal regions [Figures 2 and 3]. There were postoperative changes in the operated site and diffuse pneumocephalus which had not been present in the immediate postoperative scan obtained a few days earlier [Figure 2]. Suspecting a fulminant necrotizing wound infection with associated meningitis, broad-spectrum antibiotics were started empirically and emergency re-exploration of the wound was performed. At surgery there was soft-tissue edema with crepitus. No tissue necrosis or pus was encountered. The dura appeared intact. A thorough wound wash was given after collecting a swab. The swab grew *Acinetobacter baumannii* sensitive to colistin, netilmicin, tigecycline and ceftazidime, as well as methicillin-resistant *Staphylococcus aureus* and *Escherichia coli*. With appropriate antibiotics (colistin, vancomycin and imipenem) he improved neurologically over a period of two weeks and was discharged for further adjuvant therapy.

AB has been reported to cause necrotizing soft-tissue infections,<sup>[7]</sup> especially with war-related injuries.<sup>[8]</sup> The wound infection in our case mimicked a necrotizing soft-tissue infection which has not been earlier described in a postoperative setting. Pneumocephalus was also a very unusual occurrence. Though pneumocephalus can occur in the postoperative setting, an earlier scan (immediate postoperative scan a few days earlier) in the same patient did not show any pneumocephalus. Besides, there was no dural leak noted at resurgery (which could also have accounted for the pneumocephalus). Moreover, presence of air in the soft tissue as well as intracranial compartments supports our contention that it was a case of necrotizing wound

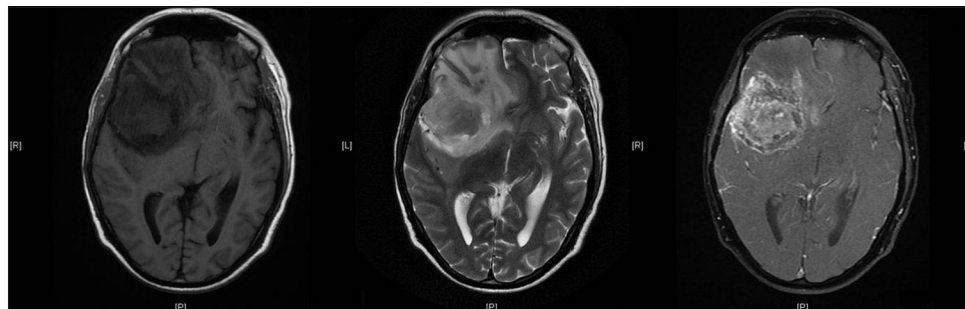
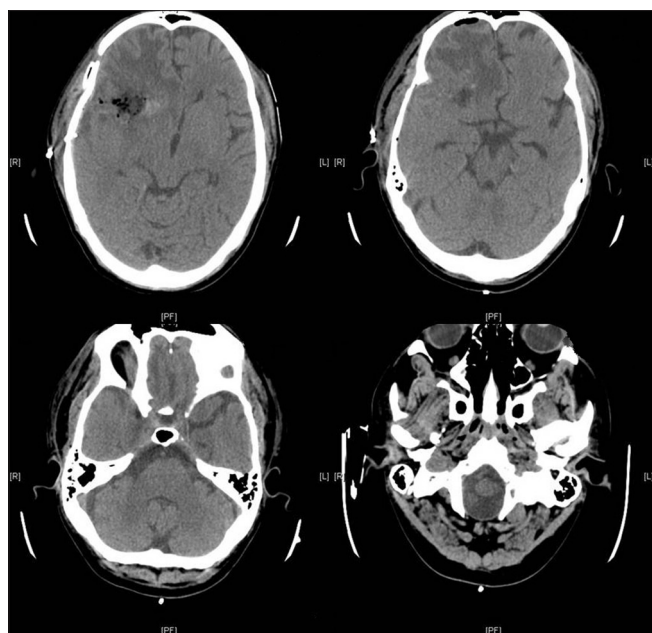


Figure 1: Preoperative magnetic resonance imaging (T1, T2 and post-contrast T1 images) showing a right frontal recurrent tumor



**Figure 2:** Immediate postoperative computed tomography scan showing only minimal air in the resection cavity

infection with meningitis producing pneumocephalus caused by AB. Spontaneous pneumocephalus due to meningitis has been reported with gas-forming as well as non gas-forming organisms.<sup>[9,10]</sup> Though AB is not gas-forming, it still causes necrotizing soft-tissue infections, and hence can even cause pneumocephalus by similar pathogenic mechanisms. Following successful treatment of the infection and improvement in clinical features, this pneumocephalus also resolved, reinforcing the association of the infection by AB and the spectrum of clinico-radiological findings.

Aliasgar V Moiyadi, Prakash Shetty,  
Sanjay Biswas<sup>1</sup>

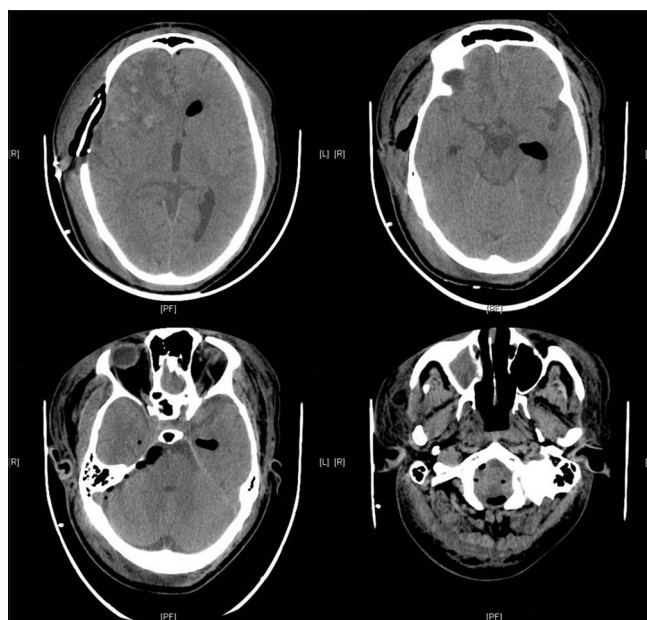
Department of Neurosurgery,  
Surgical Oncology, <sup>1</sup>Department of Microbiology,  
Tata Memorial Centre, Mumbai, Maharashtra, India

**Address for correspondence:**

Dr. Aliasgar Moiyadi,  
1221, Homi Bhabha Block,  
Tata Memorial Centre, E Borges Rd,  
Parel, Mumbai, Maharashtra, India.  
E-mail: aliasgar.moiyadi@gmail.com

**References**

1. Peleg AY, Seifert H, Paterson DL. *Acinetobacterbaumannii*: Emergence of a successful pathogen. *Clin Microbiol Rev* 2008;21:538-82.
2. Kim BN, Peleg AY, Lodise TP, Lipman J, Li J, Nation R, *et al.* Management



**Figure 3:** Subsequent computed tomography scan showing significant soft tissue and intracranial pneumocephalus

of meningitis due to antibiotic-resistant *Acinetobacter* species. *Lancet Infect Dis* 2009;9:245-55.

3. Krol V, Hamid NS, Cunha BA. Neurosurgically related nosocomial *Acinetobacterbaumannii* meningitis: Report of two cases and literature review. *J Hosp Infect* 2009;71:176-80.
4. Erdem I, Hakan T, Ceran N, Metin F, Akcay SS, Kucukercan M, *et al.* Clinical features, laboratory data, management and the risk factors that affect the mortality in patients with postoperative meningitis. *Neuro India* 2008;56:433-7.
5. Moiyadi A, Shetty P. Abscess in a metastasis. *J Neurosurg* 2010;112:474-5.
6. Sebeny PJ, Riddle MS, Petersen K. *Acinetobacterbaumannii* skin and soft-tissue infection associated with war trauma. *Clin Infect Dis* 2008;47:444-9.
7. Urschel JD. Classic diseases revisited: Necrotizing soft tissue infections. *Postgrad Med J* 1999;75:645-9.
8. Guerrero DM, Perez F, Conger NG, Solomkin JS, Adams MD, Rather PN, *et al.* *Acinetobacterbaumannii*-associated skin and soft tissue infections: Recognizing a broadening spectrum of disease. *Surg Infect (Larchmt)* 2010;11:49-57.
9. Goyal M, Sharma R, Berry M. Diffuse pneumocephalus due to meningitis: CT findings. *PediatrRadiol* 1996;26:278-9.
10. Jayaram S, Jadhav S, Rathod D, Tarvade S, Sornan A. Meningitis: An unusual cause of pneumocephalus. *J Assoc Physicians India* 2004;52:67-8.

**Access this article online**

**Quick Response Code:**



**Website:**

www.ruralneuropractice.com

**DOI:**

10.4103/0976-3147.116462