

Solitary extramedullary plasmacytoma of thoracic epidural space presenting with dorsal compressive myelopathy: A case report and review of literature

Amandeep Kumar, Guru Dutt Satyarthee, Mukund Sable¹, Vaishali Suri¹, Bhawani S. Sharma

Departments of Neurosurgery and ¹Neuropathology, All India Institute of Medical Sciences, New Delhi, India

ABSTRACT

Plasma Cell neoplasms result from monoclonal proliferation of plasma cells. Solitary extramedullary plasmacytomas (SEMPs) are rare and constitute 5% of all plasma cell disorders. SEMPs most commonly involve upper aerodigestive tract. Isolated spinal epidural space involvement by SEMPs is extremely rare and to best of our knowledge only 7 such cases have been reported previously in available English literature. We hereby present a rare case of thoracic epidural SEMP in a 32-year-old female who presented with thoracic compressive myelopathy and discuss the pertinent literature.

Key words: Compressive myelopathy, epidural, extramedullary plasmacytoma, thoracic

Introduction

Solitary plasmacytomas (SP) result from monoclonal plasma cell proliferation but lack bone marrow involvement and M protein in serum/urine, seen in multiple myeloma. SP has been classified by World Health Organisation into solitary osseous plasmacytomas (SOP) and solitary extramedullary plasmacytomas (SEMP).^[1] SEMPs are rare and constitute 5% of all plasma cell disorders and have a strong predilection for the upper aerodigestive tract.^[2] The involvement of spinal epidural space by SEMP is extremely rare.^[3-9]

We hereby describe one such rare case of thoracic epidural SEMP manifesting as dorsal compressive myelopathy.

Case Report

A 32-year-old female presented to us with a back pain for 2 months and progressive spastic weakness of bilateral lower limbs (B/L LLs) for past 8 days. The patient also had bladder involvement. Clinical examination revealed spastic weakness (power: 1/5; MRC UK) of B/L LLs, exaggerated B/L knee and ankle jerks and complete sensory loss at and below L1 level. Spine examination revealed no deformity or tenderness. With a clinical diagnosis of thoracic compressive myelopathy, thoracic spine magnetic resonance imaging (MRI) was done. MRI revealed a dorsally located epidural lesion at the level of T7-T8 vertebral bodies, which was compressing and pushing the spinal cord anterolaterally [Figure 1a and b]. The lesion was isointense on T1-weighted, hypointense on T2-weighted images and enhanced homogenously and extended into the neural foramen. The lesion did not involve bony elements [Figure 1b]. Radiologically, possibilities of tuberculosis, neurofibroma and meningioma were considered. The results of a systemic workup for tuberculosis were negative. Both meningiomas and neurofibromas are isointense to hyper intense and not hypo intense on T2-weighted images. The absence of

Access this article online

Quick Response Code:



Website:
www.ruralneuropractice.com

DOI:
10.4103/0976-3147.158794

Address for correspondence:

Dr. Amandeep Kumar, Department of Neurosurgery, All India Institute of Medical Sciences, Room No: 720, 7th Floor, Neurosciences Centre, New Delhi - 110 029, India. E-mail: aman_jagdevan@yahoo.co.in

dural tail and extension into neural foramen also pointed against meningioma.

The patient underwent T7 and T8 laminectomy and complete excision of tumor, which was reddish, soft, moderately vascular and located in epidural space with extension into the left neural foramen. The tumor could easily be separated from underlying dura and was completely excised. As there was no bony involvement and only two level laminectomy was done, no vertebral stabilization was needed.

Histopathological examination revealed diffuse and dense infiltration by mature and immature plasma cells which were immunohistochemically positive for CD138, with occasional bi-nucleated plasma cell. Based on overall histomorphological and immunohistochemical findings, the diagnosis of plasmacytoma was made [Figure 2].

Patient was then evaluated to find a systemic evidence of disease. Results of blood investigations including serum calcium and renal functions were normal. Bone marrow examination revealed <5% plasma cells and serum electrophoresis and urine examination were negative for M protein. Based on these results, diagnosis of SEMP of thoracic epidural space was made. Patient received

adjuvant radiotherapy (RT) (40 Gy in 20 fractions) to operative field.

Postoperative MRI confirmed complete excision of the tumor [Figure 1c-e]. 6 months after surgery patient has started walking (power in bilateral lower limbs: 4/5 MRC UK) and has regained bladder functions.

Discussion

Solitary extramedullary plasmacytomas most commonly involve upper aerodigestive (80–90% of cases).^[11] In 10–20% cases other body organs, including skin, testis, ovaries, liver, lungs, spleen etc., are involved.^[11] However, occurrence of SEMP as isolated masses in spinal epidural space is very rare. Thorough search of the literature revealed only seven such cases reported previously in available English literature [Table 1].

In order to make a diagnosis of SEMP, following criteria must be fulfilled:^[10]

- Biopsy from lesion showing monoclonal plasma cells
- Bone marrow plasma cell <5%
- Absence of osteolytic bone lesions or involvement of other body tissues
- Absence of hypercalcemia and renal failure
- Absent or low serum M-protein concentration. Present case fulfilled all criteria.

Radiologically, the epidural mass can be a diagnostic dilemma. In an endemic country, tuberculosis is the first consideration in the differential diagnosis, and we also considered it as first differential. Treating these patients with only antitubercular drugs is not only a futile exercise, it also has adverse consequences in terms of delaying the appropriate treatment for plasmacytoma. It is therefore important to be aware of this rare entity as a differential diagnosis of epidural masses especially when a T2-weighted hypo intense lesion is restricted to epidural space without bony

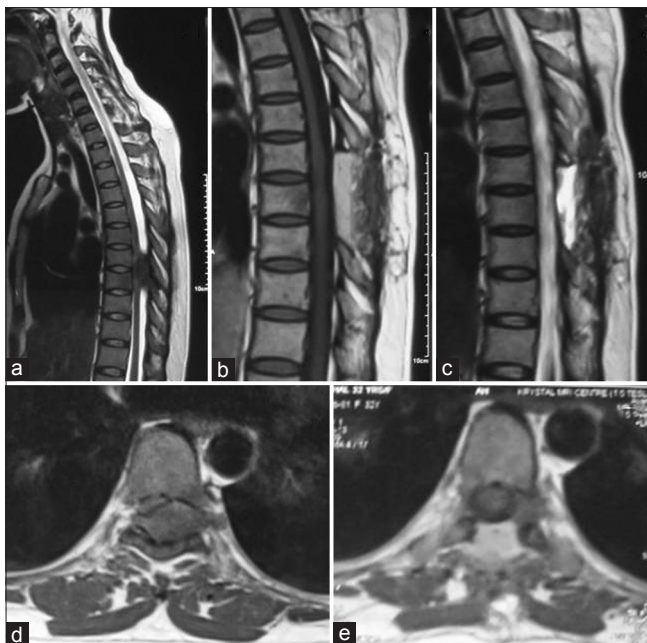


Figure 1: Magnetic resonance imaging (MRI) showing an epidural lesion at the level of T7-T8 vertebrae (a, sagittal T2-weighted), pushing the cord anterolaterally to right side and extending into the neural foramen (b, axial T2-weighted). Postoperative MRI (sagittal T1-weighted, parasagittal T2-weighted and axial T1-weighted images) revealed complete excision of the tumor with opening of the subarachnoid space (c-e) at the level of tumor. The spinal cord can be seen to have attained normal shape and position (e)

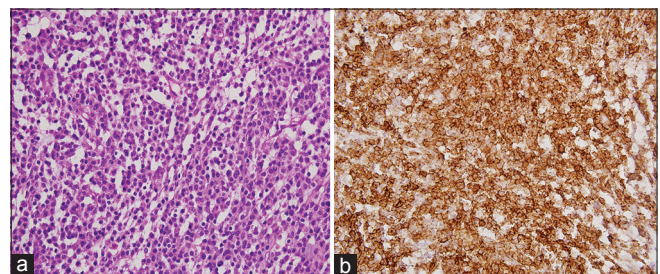


Figure 2: (a) Microphotograph showing a tumor composed of diffuse infiltration by both mature and immature plasma cells (H and E, x20) (b) plasma cells are highlighted by immunohistochemical staining for CD138 (immunohistochemistry, x40)

Table 1: Cases of epidural SEMP

Authors	Year	Age/sex	Level	Neurological deficits	Treatment	Follow-up	Results
Matsui <i>et al.</i> ^[6]	1992	52 years/male	L3	Paraesthesia lower limb	CT	19 months	Initial remission followed by recurrence and death
Palmbach <i>et al.</i> ^[8]	1996	40 years/female	C7-L2/3	Paraplegia	Plasmapheresis+RT+CT	7 months	Same
Watanabe <i>et al.</i> ^[9]	2000	85 years/male	C7-T2	Paraplegia	CT	12 months	Same
Hu <i>et al.</i> ^[4]	2001	45 years/female	L5-S1	L5-S1 radiculopathy	Resection+CT	5 months	Same
Okacha <i>et al.</i> ^[7]	2008	47 years/male	T4-T6	Paraplegia	CT+RT	6 months	Same
Avadhani <i>et al.</i> ^[3]	2010	60 years/female	T6-T7	Paraplegia	Laminectomy+RT+CT	6 months	Improved
Lourbopoulos <i>et al.</i> ^[5]	2010	45 years/male	C4-C7	Quadriparesis	GTE	13 months	Improved
Kumar <i>et al.</i> , present case	2013	32 years/female	T6-T7	Paraplegia	GTE+RT	6 months	Improved

CT: Chemotherapy, RT: Radiotherapy, GTE: Gross total excision, SEMP: Solitary extramedullary plasmacytoma

involvement and without associated paravertebral collection.

Among the 7 cases in literature^[3-9] and the present case [Table 1], both males and females are equally represented with an average age of 51 years (age range: 40–85 years). Five patients had paraparesis/paraplegia^[3,7-9] and one patient with cervical lesion had quadriparesis.^[6] Four patients had impairment of bladder and bowel functions.^[7-9]

Surgical resection followed by adjuvant therapy (chemotherapy [CT], RT or a combination of CT and RT),^[3,4] surgical resection alone,^[5] a combination of plasmapheresis, CT and RT,^[8] CT and RT^[7] and CT alone^[6,9] were different treatment regimens used in these patients [Table 1]. Among the six patients with neurological deficits (paraplegia/quadriplegia)^[3,5,7-9] three patients undergoing surgical resection showed improvement in neurological deficits^[3,5] while other three who received CT or combined CT/RT^[7-9] did not show any neurological improvement [Table 1].

According to the guidelines by the British Committee for Standards in Hematology,^[12] RT is the treatment of choice for SOPs and SEMP. The role of CT is not yet proven. The role of surgery is in providing a tissue diagnosis and in cases of spinal epidural SEMP, surgical resection relieves the compression on spinal cord thereby leading to neurological improvement.

Conclusion

Epidural SEMP are very rare and require a high index of suspicion for diagnosis and appropriate management as both clinical manifestations and radiological features can be quite similar to other more common pathologies in this region. Though RT is the treatment of choice for

SP, surgical resection helps in providing tissue diagnosis and relieving spinal cord compression.

References

1. Campo E, Swerdlow SH, Harris NL, Pileri S, Stein H, Jaffe ES. The 2008 WHO classification of lymphoid neoplasms and beyond: Evolving concepts and practical applications. *Blood* 2011;117:5019-32.
2. Majumdar S, Raghavan U, Jones NS. Solitary plasmacytoma and extramedullary plasmacytoma of the paranasal sinuses and soft palate. *J Laryngol Otol* 2002;116:962-5.
3. Avadhani A, Shetty AP, Rajasekaran S. Isolated extraosseous epidural myeloma presenting with thoracic compressive myelopathy. *Spine J* 2010;10:e7-e10.
4. Hu KC, Lin J, Chuang YC, Cheng SJ, Chang KM. Multiple myeloma associated with extramedullary plasmacytoma causing nerve root compression: A case report. *J Formos Med Assoc* 2001;100:277-80.
5. Lourbopoulos A, Ioannidis P, Balogiannis I, Stavrinou P, Koletsis T, Karacostas D. Cervical epidural plasmacytoma presenting as ascending paraparesis. *Spine J* 2011;11:e1-4.
6. Matsui H, Fujie H, Tsuji H. Extraosseous epidural tumor of immunoglobulin D myeloma. *J Spinal Disord* 1992;5:366-9.
7. Okacha N, Chrif E, Brahim E, Ali A, Abderrahman E, Gazzaz M, *et al.* Extraosseous epidural multiple myeloma presenting with thoracic spine compression. *Joint Bone Spine* 2008;75:70-2.
8. Palmbach M, Hoffmann W, Grodd W, Postler E, Voigt K. Extraosseous, epidural tumor spread of multiple myeloma. *Eur J Radiol* 1996;22:146-8.
9. Watanabe Y, Endou A, Ooi S, Matsushima E, Shimisu Y, Nakashima K. Extraosseous epidural IgD myeloma presenting with compression myelopathy. *Psychiatry Clin Neurosci* 2000;54:665-7.
10. Soutar R, Lucraft H, Jackson G, Reece A, Bird J, Low E, *et al.* Guidelines on the diagnosis and management of solitary plasmacytoma of bone and solitary extramedullary plasmacytoma. *Br J Haematol* 2004;124:717-26.
11. Alexiou C, Kau RJ, Dietzfelbinger H, Kremer M, Spiess JC, Schratzenstaller B, *et al.* Extramedullary plasmacytoma: Tumor occurrence and therapeutic concepts. *Cancer* 1999;85:2305-14.
12. British Committee for Standards in Haematology. Guidelines on the diagnosis and management of solitary plasmacytoma of bone and solitary extramedullary plasmacytoma. *British Journal of Haematology* 2004;124:717-26.

How to cite this article: Kumar A, Satyarthee GD, Sable M, Suri V, Sharma BS. Solitary extramedullary plasmacytoma of thoracic epidural space presenting with dorsal compressive myelopathy: A case report and review of literature. *J Neurosci Rural Pract* 2015;6:410-2.

Source of Support: Nil. **Conflict of Interest:** None declared.