

Multiple oligodendroglioma with pseudoprogression

Junko Matsuyama

Department of Neurosurgery, Fujita Health University, 1-98, Dengakugakubo, Kutsukake, Aichi, Japan

ABSTRACT

A 72 year-old male hospitalized with aphasia, abnormal behavior, and rapidly progressive dementia. Magnetic resonance imaging (MRI) enhanced by contrast media demonstrated multiple brain tumors in left parietal lobe and left paraventricular region. Biopsy was performed, and histopathological examination and genetical evaluation revealed anaplastic oligodendroglioma. Local radiation 50Gy was given, and Temozolomide via orally administered for 42 days. After the chemoradiotherapy, even though the parietal tumor showed lessening of the size, enlargement of the tumor in the left paraventricular region was observed, and we considered that phenomenon was pseudoprogression. 5 courses of Temozolomide therapy was added, but cerebellar tumor appeared and enlarged with hydrocephalus, and died 1 year and 3 months after the first hospitalization.

Key words: Anaplastic, multiple oligodendroglioma, pseudoprogression, temozolomide

Introduction

Although, the incidence of multicentric glioma accounts nearly 2.5% of all gliomas, most cases are glioblastoma or anaplastic gliomas.^[1,2] Oligodendroglioma cells are detectable in the cerebrospinal fluid in up to 14% of patients, and we recently treated a case of multiple anaplastic oligodendrogliomas, describe the case in detail and discuss the distinction between “multicentric” and “dissemination via cerebrospinal pathways” and the treatment.

Case Report

A 72-year-old man revealed aphasia, abnormal behavior, and rapidly progressive dementia since October 13, 2009, and hospitalized in our department on Oct. 17, 2009. Magnetic resonance imaging (MRI) enhanced by contrast media demonstrated multiple brain tumors in left parietal lobe and left paraventricular region [Figure 1a]. Computed tomography (CT) scan showed high density

of microbleeding in the left paraventricular region [Figure 1b]. Biopsy for the tumor in the left parietal tumor was performed. In the permanent section, the hematoxylin and eosin-stained specimen showed that the tissue was composed of cells with clear cytoplasm and with round or irregular nuclei having dense chromatin (so called honey comb appearance) that existed in between highly proliferative vasculature [Figure 2]. The nuclei had pleomorphism and a variety of size, a lot of mitosis were observed. Microvascular proliferation and necrotic findings were also seen. Occasionally, calcification deposit and microbleeding were observed. Immunocytochemical study showed positive for glial fibrillary acidic protein, strongly positive for the olig-2 (oligodendrocyte lineage genes) stain. MIB-1 labeling index was 68%. These findings were compatible for anaplastic oligodendroglioma, so genetical evaluation was performed, showing loss of heterozygosity (co-deletions) in chromosome 1p19q. Local brain for the left parietal region radiotherapy was given to a total dose of 50Gy, in 34 fractions of 1.5Gy daily on weekdays from November to December, 2009. At the same time, Temozolomide of 120mg daily was orally administered for 42 days. MRI was performed just after these combined chemo- and radiotherapy showed lessening of the mass effect in the left parietal tumor, but enlarging the size of the tumor in the left paraventricular region [Figure 3]. We considered that enlargement of the paraventricular tumor was pseudoprogression, as consolidating therapy, Temozolomide of 240mg daily (150mg/m²/day) for

Access this article online

Quick Response Code:



Website:

www.ruralneuropractice.com

DOI:

10.4103/0976-3147.102636

Address for correspondence:

Dr. Junko Matsuyama, Department of Neurosurgery, Fukushima Medical University and Minamisoma city general hospital, 2-54-6, Takami, Haramachi, Minamisoma, Fukushima, Japan. E-mail: jmatsu@fujita-hu.ac.jp

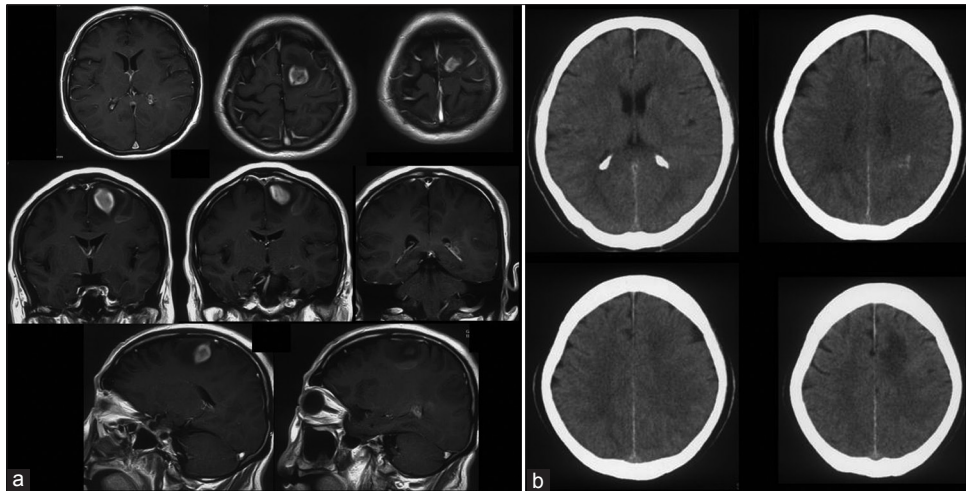


Figure 1: (a) Magnetic resonance imaging (MRI) enhanced by contrast media obtained at the first hospitalization. Multiple brain tumors in the left parietal and left paraventricular region were observed. Upper: axial view, middle: coronal view, lower: sagittal view. (b) Computed tomography (CT) scan at the first hospitalization. Microbleeding in left paraventricular region was observed

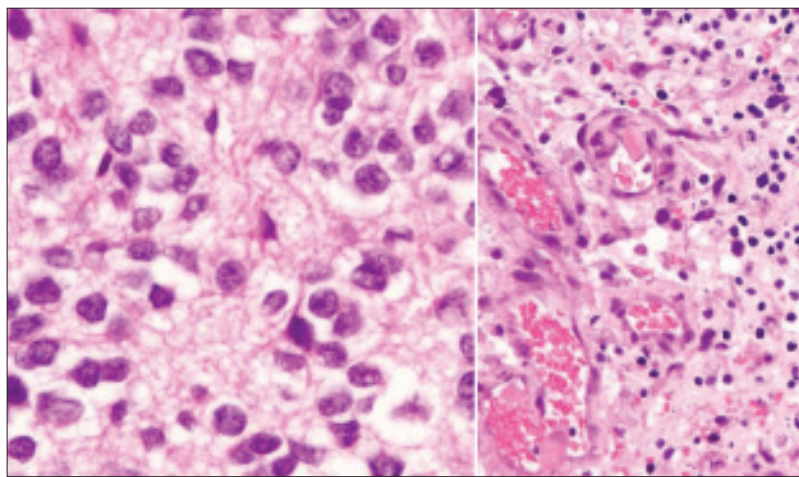


Figure 2: Histopathological findings of the tumor specimen. The tissue was composed of cells with clear cytoplasm and with round or irregular nucleus having dense chromatin (so called honey comb appearance). Microvascular proliferation was also observed. Hematoxylin and eosin-stained specimen, $\times 400$

5 days was orally administered for 5 times from February to October 2010 at outpatient clinic. Despite of the high levels of promoter hypermethyltransferase (MGMT) activity, temozolomide is the first line chemotherapeutic agent against anaplastic oligodendroglioma,^[3,4] so we tried temozolomide. But during those period, cerebellar tumor appeared and gradually enlarged and hydrocephalus was observed [Figure 4]. In October 2010, one cycle of Temozolomide via intravenous administration was performed and lessening of the mass effect was seen, so the patient was transferred to rehabilitation hospital. In the end of November 2010, the patient's consciousness deteriorated because of the enlargement of the 4th ventricle tumor, hydrocephalus and abnormality of serum electrolyte. The consciousness of the patient recovered for a while by correcting the electrolyte balance, but consciousness level worsened

again, and respiration and clinical state was deteriorated, and died on January, 2011.

Discussion

The incidence of multicentric glioma is reported to be approximately 2.5% of all gliomas. Most cases are glioblastoma or anaplastic astrocytoma, and oligodendroglioma is very rare.^[1,2] Salvati M. *et al.* reported 25 cases with multicentric gliomas, 11 cases are multicentric glioblastomas, 6 cases are multicentric anaplastic astrocytomas, and other cases are combinations of glioblastomas, anaplastic astrocytomas, and low grade gliomas, and no oligodendrogliomas were found.^[5]

We considered whether our patient's tumor was

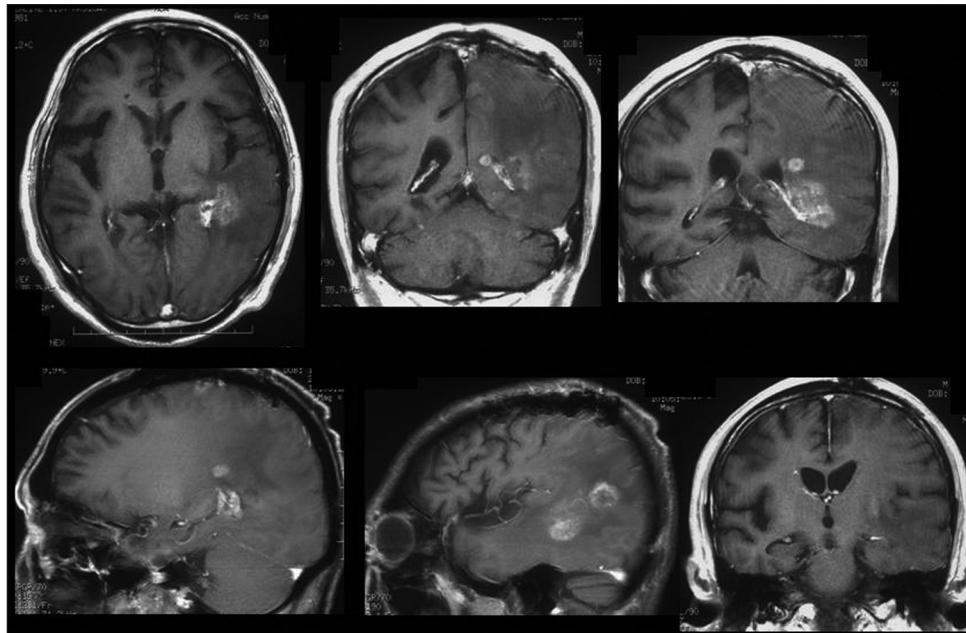


Figure 3: MRI after radiotherapy 50Gy and Temozolomide of 120mg daily for 42 days. Although, lessening of the mass effect of left parietal tumor was observed, enlargement of the paraventricular tumor was seen, which seemed to be pseudoprogression

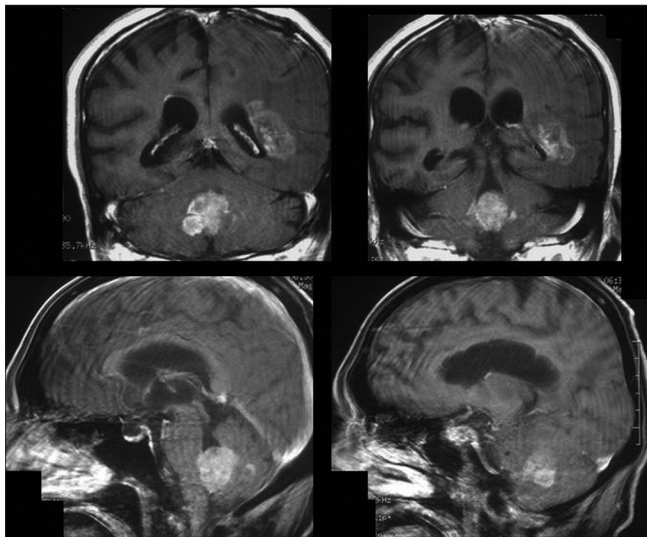


Figure 4: MRI performed about 1 year after initial hospitalization. Cerebellar tumor was observed and enlarged with hydrocephalus. It was not detected in the initial MRI at the first hospitalization

multicentric or metastatic. Solomon et al. stated a clear distinction must be made, in cases of multiple tumors, among dissemination via cerebrospinal pathways, direct extension across commissures, satellitosis, and true multicentricism.^[6] Multicentric tumors are widely separated, arising in different lobes or hemispheres, which is not readily explained by one of the pathways mentioned above. In our case, the 4th ventricle tumor which arose about 1 year after initial treatment might have been a metastasis via cerebrospinal fluid, although one of the multiple sites cannot be dismissed entirely. However,

left parietal tumor and left trigonal area tumor were found at the same time, and those two tumors were separated, arising in the distinct sites, and were not explained either by the dissemination via cerebrospinal pathways or direct extensions, so we considered those tumors were multicentric. The pathogenesis of multicentric gliomas is unknown. The most quoted hypothesis is the two-step process reported by Willis.^[7] In the first stage a large area of the brain undergoes neoplastic transformation, while in the second stage one or more foci of tumor proliferation develop within the affected area, giving origin to separate lesions. The pathogenesis of multicentric glioma includes the embryonal rest theory and the two-stage theory, but Zülch pointed out the metastasis via an unknown pathway.^[8]

Multicentric gliomas are characterized by rapid progression, which may be related to the fact that they tend to exhibit malignant features on histology, this fact is also valid for the oligodendrogliomas. The course of our case from initial diagnosis to death was 1 year and 3 months, despite of the combined chemoradiotherapy. In our case, the 4th ventricle portion tumor which appeared about one year after the initial treatment and was not detected in the MRI taken at initial hospitalization, might be the metastasis via cerebrospinal fluid, as histological type of malignant oligodendroglioma is a risk factor of cerebrospinal fluid dissemination.^[9]

Finally, the tumor in the left paraventricular region showed progression even just after the temozolomide treatment, and we presumed it was pseudoprogression,

because in the first 6 months of post-chemoradiotherapy period, showed a high incidence of pathologically confirmed pseudoprogression associated with treatment-related necrosis without viable tumor cells. Various imaging techniques including MR spectroscopy have been studied but neither has been found to be powerful to identify pseudoprogression, and unfortunately, the diagnosis of pseudoprogression still depends on pathologic examination. The disruption of blood-brain barrier with the resultant observation of an early radiologic increase in contrast enhancement at MRI, which may falsely mimic true progression,^[10] and this fact made the treatment of this case more complicated.

References

- Ogasawara H, Kiya K, Uozumi T, Sugiyama K, Kawamoto K, Ohta M. Multiple oligodendroglioma case report. *Neurol Med Chir (Tokyo)* 1990;30:127-31.
- Daneyemez M, Baysefer A, Can C, Timurkaynak E. Multiple oligodendroglioma: Case report. *Minim Invasive Neurosurg* 2000;43:51-2.
- van den Bent MJ, Taphoorn MJ, Brandes AA, Menten J, Stupp R, Frenay M, *et al.* Phase II study of first-line chemotherapy with temozolomide in recurrent oligodendroglial tumors: The European Organization for Research and Treatment of Cancer Brain Tumor Group Study 26971. *J Clin Oncol* 2003;21:2525-8.
- Hegi ME, Diserens AC, Gorlia T, Hamou MF, de Tribolet N, Weller M, *et al.* MGMT gene silencing and benefit from temozolomide in glioblastoma. *N Engl J Med* 2005;352:997-1003.
- Salvati M, Caroli E, Orlando RE, Frati A, Artizzu S, Ferrante L. Multicentric gliomas: Our experience in 25 patients and critical review of the literature. *Neurosurg Rev* 2003;26:275-9.
- Solomon A, Perret GE, McCormick WF. Multicentric gliomas of the cerebral and cerebellar hemispheres. *J Neurosurg* 1969;31:87-93.
- Willis RA. Pathology of tumors. London: Butterworth; 1960. p.121-2.
- Zülch KJ. Brain tumors. Their biology and pathology. 1st ed. New York: Springer; 1957. p. 74-6, 116-20, 240-58.
- Grabb PA, Albright AL, Pang D. Dissemination of supratentorial malignant gliomas via the cerebrospinal fluid in children. *Neurosurgery* 1992;30:64-71.
- Topkan E, Topuk S, Oymak E, Parlak C, Pehlivan B. Pseudoprogression in patients with glioblastoma multiforme after concurrent radiotherapy and temozolomide. *Am J Clin Oncol* 2012;35:284-9.

How to cite this article: Matsuyama J. Multiple oligodendroglioma with pseudoprogression. *J Neurosci Rural Pract* 2012;3:379-82.
Source of Support: Nil. **Conflict of Interest:** None declared.