

Optic Perineuritis in a Case of Tolosa–Hunt Syndrome

Teena Mariet Mendonca¹ Basavaprabhu Achappa² Sumana J. Kamath¹ Gladys Reshma Rodrigues¹

¹Department of Ophthalmology, Kasturba Medical College, Mangalore; Manipal University of Higher Education (MAHE), Manipal, Karnataka, India

²Department of Internal Medicine, Kasturba Medical College, Mangalore; Manipal University of Higher Education (MAHE), Manipal, Karnataka, India

Address for correspondence Teena Mariet Mendonca, MS, Department of Ophthalmology, Kasturba Medical College Hospital, Attavar, Mangalore 575001, Karnataka, India (e-mail: tmendonca87@gmail.com).

J Neurosci Rural Pract 2019;10:504–505

A 50-year-old woman presented with the complaints of recurrent episodes of right hemicranial headache for 7 months with binocular diplopia for 1 month. Headache was severe in nature with shooting type of right periorbital and retro-orbital pain. On examination, her visual acuity was 20/20 for distance and N6 for near in both eyes. She had complete ptosis and total ophthalmoplegia of the right eye. Right-eye pupil was 4 mm dilated and fixed. Left-eye pupil was 2 mm reacting to light. Fundus examination showed optic disc edema in the right eye. We arrived at a clinical diagnosis of total ophthalmoplegia with orbital apex syndrome on the right side. Her visual field examination (Humphrey 30–2) was normal in both eyes. Magnetic resonance imaging (MRI) study orbits (plain) showed ill-defined T1 and T2 isointense area noted in the right orbital apex and superior orbital fissure. Contrast-enhanced MRI orbit images (→ Fig. 1A) showed right optic nerve sheath enhancement predominantly in the orbital apex. Coronal sections showed “doughnut-”shaped enhancement, and axial sections showed “tram track” enhancement (→ Fig. 1B) around the optic nerve suggestive

of optic perineuritis. She underwent extensive workup to rule out autoimmune and infective conditions. The patient was diagnosed with Tolosa–Hunt syndrome with optic perineuritis. She was treated with intravenous methylprednisolone 1 g/day for 5 days followed by oral prednisolone 1 g/kg body weight with a slow taper. Dramatic improvement in her symptoms was noted within 48 hours of steroid administration. She was relieved of headache and diplopia. Her extraocular motility improved significantly, and disc edema resolved after a week of starting steroids.

Tolosa–Hunt syndrome, also called syndrome of painful ophthalmoplegia, is a diagnosis of exclusion. The syndrome results in periorbital or hemicranial pain with ipsilateral paresis of oculomotor nerves due to nonspecific inflammation at the orbital apex or superior orbital fissure.¹ Optic perineuritis is an uncommon variant of idiopathic orbital inflammatory disorder, involving the optic nerve sheath and surrounding tissues.² Contrast-enhanced MRI orbits is the diagnostic modality of choice. Visual outcome after treatment with corticosteroids in patients with optic perineuritis is generally good.³

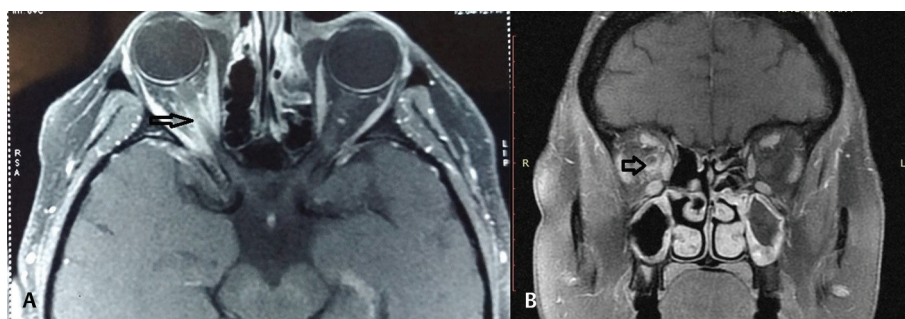


Fig. 1 Contrast-enhanced magnetic resonance imaging brain with orbits (T1-weighted image) axial section (A) showing ill-defined homogeneously enhancing area noted in the right orbital apex. “Tram track” enhancement (arrow) of the optic nerve sheath in the axial section and “doughnut-”shaped enhancement (arrow) in the coronal section (B) can be noted.

Funding

None.

Conflict of Interest

None declared.

- 2 Purvin V, Kawasaki A, Jacobson DM. Optic perineuritis: clinical and radiographic features. *Arch Ophthalmol* 2001;119(9):1299–1306
- 3 Wasmeier C, Pfadenhauer K, Rösler A. Idiopathic inflammatory pseudotumor of the orbit and Tolosa-Hunt syndrome—are they the same disease? *J Neurol* 2002;249(9):1237–1241

References

- 1 Kline LB, Hoyt WF. The Tolosa-Hunt syndrome. *J Neurol Neurosurg Psychiatry* 2001;71(5):577–582